

NON-SMALL CELL LUNG CANCER LEFT UPPER LUNG



St. Joseph's Hospital and Medical Center

CHW

St. Joseph's Hospital/Arizona Oncology Services
CyberKnife® Team:

Radiation Oncologist: John Kresl, M.D., Ph.D.

Medical Physicist: Ray Rodebaugh, Ph.D.

Radiation Therapist: Nancy Bernstein, R.T.(T.)

CyberKnife Center: St. Joseph's Hospital/
Arizona Oncology Services
Phoenix, AZ

NON-SMALL CELL LUNG CANCER LEFT UPPER LUNG

DEMOGRAPHICS

Sex: Female
Age: 65
Histology: Poorly differentiated non-small cell lung carcinoma with focal squamous features as T1 N0 M0 stage grouping I

CLINICAL HISTORY

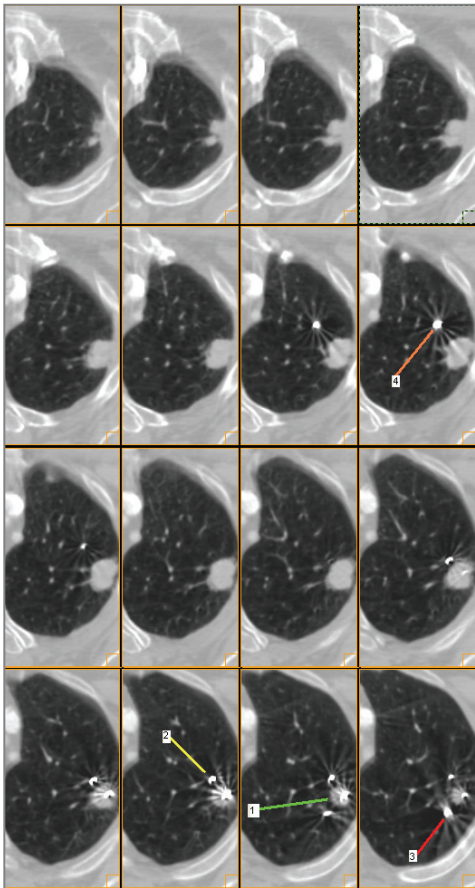
Referred by: Pulmonologist
Previous Treatment: None

Case History

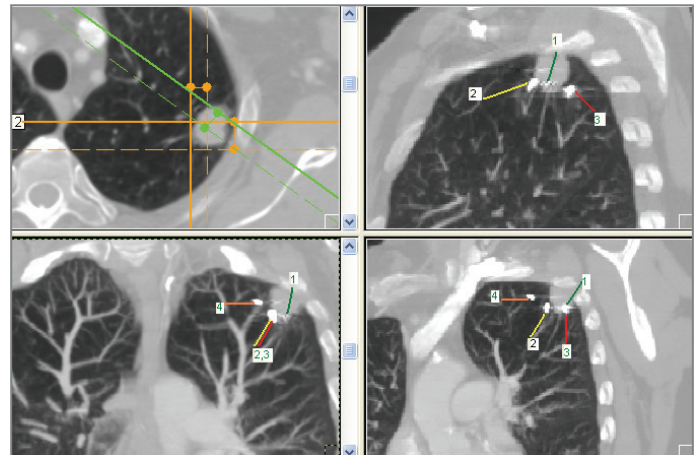
A screening chest X-ray demonstrated a 1.5 x 2.0 cm pulmonary nodule in the left upper lobe. Diagnostic images two years earlier demonstrated no evidence of a pulmonary nodule. A PET/CT scan identified a left upper pulmonary nodule with a maximum SUV of 22.7, suspicious for pulmonary lung malignancy. There was no evidence of distant disease. A CT-guided needle biopsy obtained a 0.1 x 1.2 cm sample of tissue; pathologic review of the biopsy specimen was consistent with poorly differentiated non-small cell lung cancer (NSCLC).

CyberKnife® Treatment Rationale

The patient refused surgery because she was concerned about a prolonged recovery. Her other treatment option in a non-surgical setting was radiation therapy. It was determined that the patient would be best treated with a stereotactic radiosurgery approach. Recent studies had shown that stereotactic body radiation therapy¹ had achieved therapeutic outcomes in the short run that approximated those achieved with surgical resection. Other studies revealed the feasibility of CyberKnife® treatment of lung lesions.^{2,3}



Pretreatment CT: Sixteen consecutive 1.25 mm axial CT slices demonstrate an ovoid tumor dimension of 1.5 x 2.0 x 2.1 cm. Note the location of the four fiducials within the tumor and in close proximity to the tumor in the lung parenchyma.



Pretreatment CT: Multiplanar reformatted images show the lung tumor with four fiducials positioned in relationship to the ribs, bronchi and other anatomical landmarks.

TREATMENT DETAILS

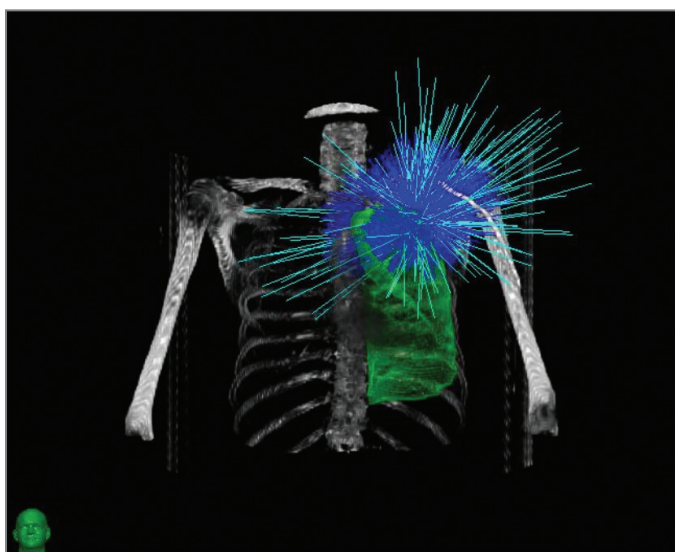
Tumor Volume: 13.85 cc
Imaging Technique(s): CT, MRI
Rx Dose & Isodose: 48 Gy to 71%
Conformality Index: 1.37
Tumor Coverage: 99.6%
Number of Beams: 154

Fractions: 3
Path Template: 3 paths 900_1000 mm
Tracking Method: Synchrony® Tracking System
Collimator(s): 15 mm

Treatment Planning Process

The patient was treated with CyberKnife® Robotic Radiosurgery, which precisely targeted multiple non-isocentric, non-coplanar beams at the tumor. This delivered a large dose of radiation to a small field while sparing surrounding normal tissues and other critical structures. Prior to the procedure, the patient had permanent fiducial markers placed near the treatment site, then was immobilized in an Alpha cradle. MRI and CT were performed and data were transferred to the CyberKnife treatment planning computer where an optimal treatment plan was produced.

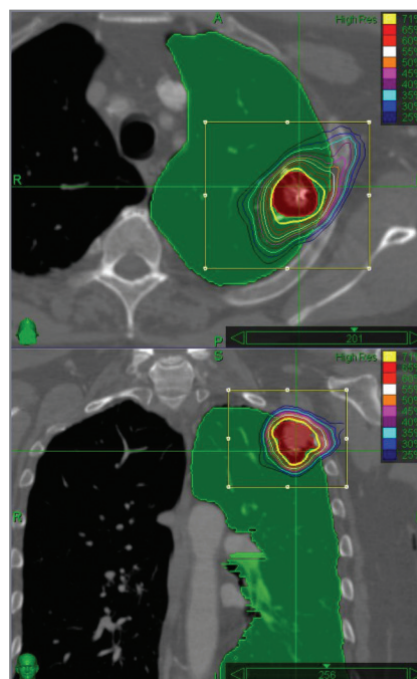
On each of the axial slices the gross tumor volume (GTV) was outlined to digitally reconstruct a 3-dimensional planning tumor volume (PTV) that measured 13.85 cc. The PTV had a 5-mm margin with respect to the GTV. A treatment plan was developed using 154 separately targeted beams from 72 unique robotic positions with the 15.0-mm collimator. The treatment plan was to deliver 48 Gy in 3 fractions of 16 Gy each. This dose was prescribed to the margin of the target volume at the 71% isodose line. This resulted in a homogeneity index of 1.41, a maximum tumor dose of 67.61 Gy, and a conformality score of 1.37, with 99.6% coverage of the target volume.



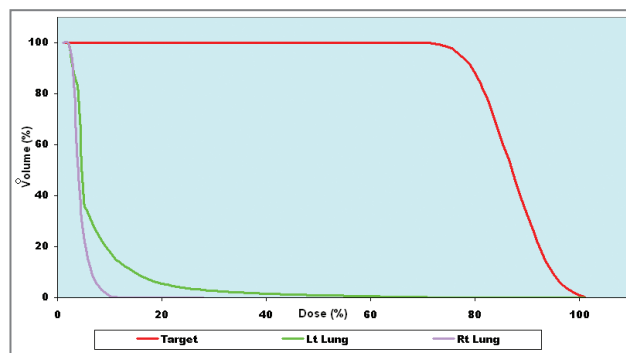
Anterior-posterior 3D rendering of bony anatomy, segmented lung, and beam orientations and intensities.

Treatment Delivery

The patient was immobilized in an alpha cradle. The treatments were delivered on 3 consecutive days using the Synchrony® treatment module to compensate for patient movement and respiration during treatment. The patient tolerated the treatment well, experiencing no ill effects or changes in her pulmonary status during the therapy.



Axial and coronal planning images showing the tumor, lung parenchyma and isodose curves.



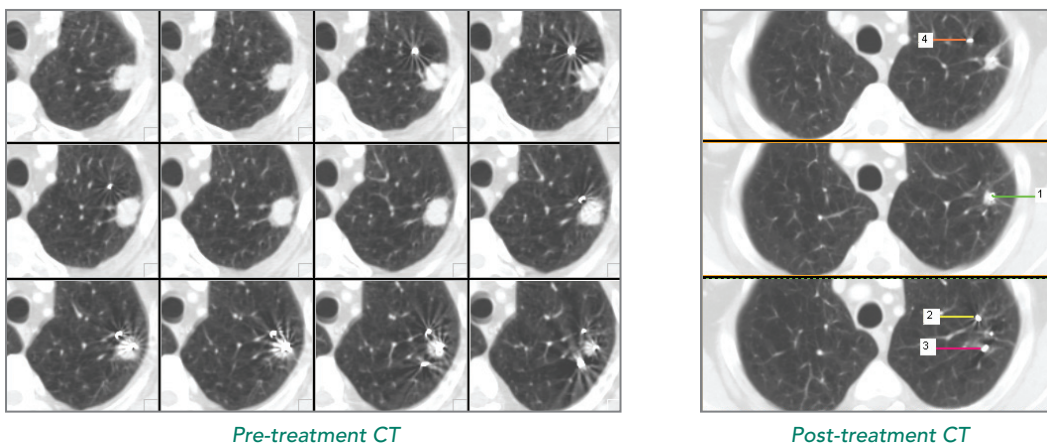
Dose-volume histogram (DVH) showing the dose delivered to the tumor and left and right lung.

Outcome and Follow-Up

- Three months after treatment, the patient reported no evidence of local regional recurrence or treatment-related toxicity
- She had a radiographically complete response to her Synchrony® based CyberKnife® radiosurgery treatment for NSCLC in less than 15 weeks; the radiologist interpreted the lesion to have been surgically removed as noted in the radiology report of the patient's 3-month follow-up CT scan, "interval resection of the left upper lobe mass lesion with multiple surgical clips seen at the region. There is a nodular component with some streaky opacities that extend from the area of the clips to the pleural space and likely represents areas of postoperative scarring."
- A follow-up PET/CT scan at ten months was negative at the site of the primary tumor and showed no evidence of disease

Conclusion and CyberKnife Advantages

- This patient had an excellent initial outcome including a radiographically complete response with CyberKnife Robotic Radiosurgery using Synchrony motion compensation in the treatment of NSCLC
- The CyberKnife System has the potential to be an excellent treatment alternative for those lung tumor patients who are poor surgical candidates or who refuse surgery



Pre / Post CyberKnife RRS Image Comparison: The three 3-month post-treatment sections on the right, with the 4 fiducials identified, correspond to the twelve 1.25 mm CT pre-treatment slices on the left. This comparison shows the radiographically complete response in less than 15 weeks after treatment with some residual fibrosis (top right image).

ST. JOSEPH'S HOSPITAL AND MEDICAL CENTER / ARIZONA ONCOLOGY SERVICES

St. Joseph's Hospital and Medical Center, Phoenix, AZ (www.stjosephs-phx.org) is a highly regarded 520 bed non-profit medical center founded in 1895. Arizona Oncology Services (AOS) (www.azoncology.com) is the one of the largest Radiation Oncology treatment programs in the Southwest and annually performs over 500 Stereotactic Radiosurgery treatments. Dr. Kresl is the Co-Medical Director of the Barrow Neurological Institute CyberKnife Center and actively participates in national Clinical Oncology Treatment Protocols that offer the most advanced forms of treatment for tumors of all disease sites. The center's cases are 70% intracranial, 14% spine and 16% whole body over the past year. The CyberKnife is used on those patients for whom traditional radiosurgery is not possible or in situations where patients specifically request this procedure over other options.

References

1. Timmerman R, Papiez L, McGarry R et al. Extracranial stereotactic radioablation: results of a phase I study in medically inoperable stage 1 non-small cell lung cancer Chest 124:1946-1955, 2003.
2. Whyte RI, Crownover R, Murphy MJ et al, Stereotactic radiosurgery for lung tumors: preliminary report of a phase I trial, The Annals of Thoracic Surgery 75(4), 1097-1101, 2003.
3. Pennathur A, Luketich JD, Burton S, et al. Stereotactic radiosurgery for the treatment of lung neoplasm: initial experience , The Annals of Thoracic Surgery 83:1820-1824, 2007.

