

## PERINEAL RELAPSE OF PROSTATE CARCINOMA



San Bortolo Hospital CyberKnife® Team:

Radiation Oncologists: Gino Panizzoni, M.D.  
Rosabianca Guglielmi, M.D.

Neurosurgeon/  
Radiation Oncologist: Federico Colombo, M.D.

Medical Physicists: Paolo Francescon, Ph.D.  
Carlo Cavedon, Ph.D.  
Stefania Cora, Ph.D.  
Paolo Scalchi, Ph.D.

Urologist: Andrea Tasca, M.D.

CyberKnife Center: San Bortolo Hospital  
Vicenza, Italy

## PERINEAL RELAPSE OF PROSTATE CARCINOMA

### DEMOGRAPHICS

Sex: M  
Age: 67  
Histology: Adenocarcinoma (Gleason = 9 (5 + 4))

### CLINICAL HISTORY

Referred by: Urologist  
Past Medical History: Hormonal therapy, radical prostatectomy, conformal radiotherapy

### Case History

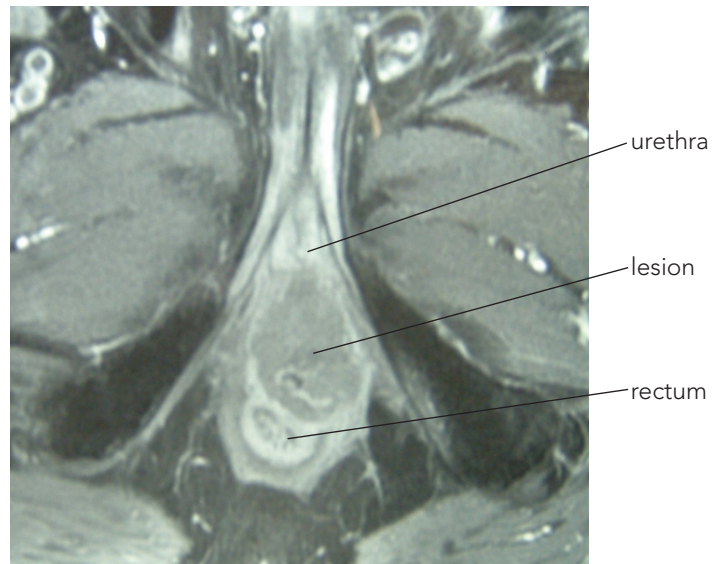
This 67-year-old male was diagnosed with prostate carcinoma, with a PSA of 18 ng/ml. Treatment commenced with neoadjuvant hormonal therapy (bicalutamide 150 mg/day). Three months later a radical prostatectomy was performed. An adenocarcinoma with necrosis, angiolymphatic and perineural infiltrations was found.

Hormonal adjuvant therapy (bicalutamide 50 mg/day) was pursued and conformal adjuvant radiotherapy was performed three months after surgery, reaching a dose of 64 Gy in 32 fractions. Four months later the patient developed a perineal relapse in the apex region, near the posterior urethra, confirmed by histology and apparent on rectal examination as a 4 cm diameter mass. Hormonal therapy was terminated.

The patient began to experience perineal pain, rectal and urinary incontinence, and his PSA increased to 21.4 ng/ml two months after cessation of hormone therapy. The only surgical option was radical pelvectomy, which was refused by the patient. Further radiotherapy and IMRT were excluded because of the dose already delivered.

### CyberKnife® Treatment Rationale

We hypothesized that stereotactic radiosurgery may provide a similar benefit to surgery with the advantage of sparing the pelvic organs from major toxicity. The CyberKnife System has made extracranial radiosurgery possible by coupling highly conformal radiation delivery with precise targeting based on real-time imaging. We selected this technique for this patient in order to avoid the significant morbidity associated with further surgery.



*Pre-treatment T2-weighted MRI. The lesion is shown after radical prostatectomy, near the urethra, and with infiltration of the anal sphincter. The lesion diameter is 5 cm.*

**TREATMENT DETAILS**

Tumor Volume: 18.95 cm<sup>3</sup>  
 Imaging Technique(s): CT  
 Rx Dose & Isodose: 24 Gy to 80%  
 Conformality Index: 1.34  
 Tumor Coverage: 90.1%  
 Number of Beams: 114

Fractions / Treatment Time: 3 / 45 minutes  
 Path Template: 3 path 900\_1000 mm  
 Tracking Method: 6D Fiducial Tracking  
 Collimator(s): 30 mm

**Treatment Planning Process**

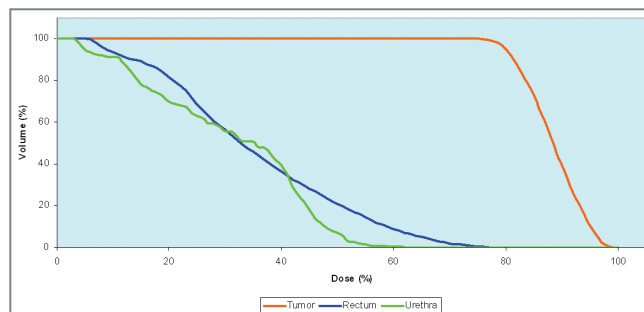
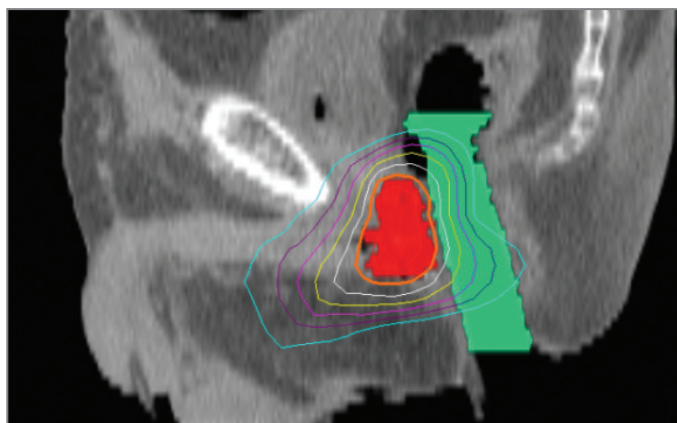
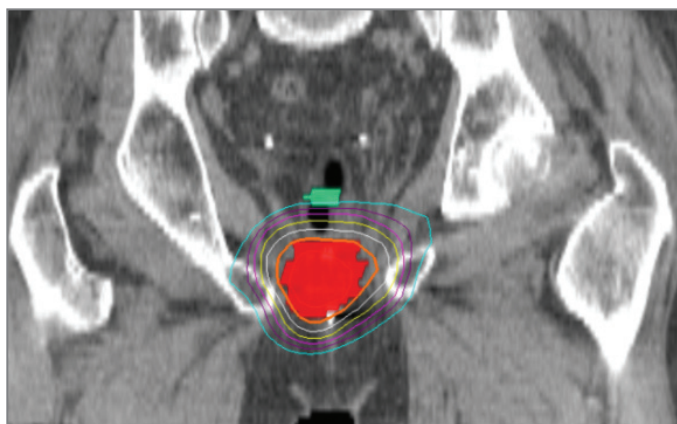
The patient had 4 gold fiducial markers implanted in the tumor for targeting purposes by ultrasound-guided trans-perineal needle insertion (19 gauge pre-loaded) after prior antibiotic prophylaxis and enema. A vacuum bag immobilization device was custom made for him two weeks after fiducial placement. A CT scan was performed with the patient in the feet-first supine treatment position 14 days after fiducial placement, with a retaining catheter to show the urethra and a rigid rectal balloon to reduce rectum and tumor movements.

The clinical target volume (CTV) and the regions of interest (ROI; rectum, urethra, and bladder) were delineated on cross-sectional CT images. A radiosurgical conformal treatment plan was generated based on tumor and ROI dose constraints.

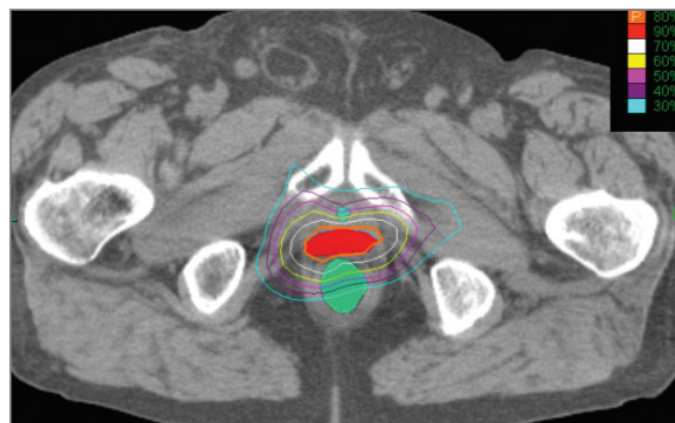
**Treatment Delivery**

Treatment was divided into three daily fractions of 8 Gy to the 80% isodose surface. The urethra received a maximum of 4 Gy per fraction to less than 50% of its volume. Only 1.4% of the rectal wall received the full prescribed dose with the volume receiving 50% of the prescribed dose limited to 21%.

During treatment the rigid rectal balloon created a mechanical separation between the entire rectal volume and the lesion, reducing the dose delivered to the lateral and posterior rectal wall and also limiting target motion due to intra-treatment rectal volume changes. The fiducials were localized by orthogonal X-rays and the treatment geometry was automatically corrected throughout treatment delivery.



Cumulative Dose Volume Histogram (DVH) showing dose delivered to the Tumor, Rectum, and Urethra.



The treatment plan shown in coronal (top), sagittal (bottom) and axial (right). The tumor volume is displayed in red, the urethra and rectum are in green, the 80% isodose line is displayed in orange.

### Outcome and Follow-Up

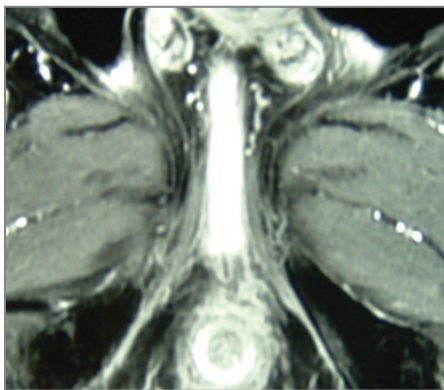
Acute morbidity was evaluated using the EORTC/RTOG scoring system and was no greater than Grade 1. Pain disappeared two weeks after the end of radiosurgical treatment. Rectal incontinence improved, but no changes were observed in urinary incontinence. A month later the patient underwent follow-up examination and no lesion was found at rectal exploration. An ultrasound examination confirmed the complete response to this treatment: no mass was seen. His PSA was reduced to 2.8 ng/ml.

Four months post-treatment the patient underwent an MRI examination that again showed a complete response: no masses were detectable in the posterior urethra. The MRI was repeated at 8 months post-treatment with the same result. One year after treatment no relapses were found with a trans-rectal ultrasonography examination. Eighteen months post-treatment the patient was in good health with a PSA of 0.3 ng/ml. Urinary incontinence was unchanged from pre-treatment and rectal incontinence remained absent. Contrast-enhanced CT shows complete absence of disease in the perineal region.

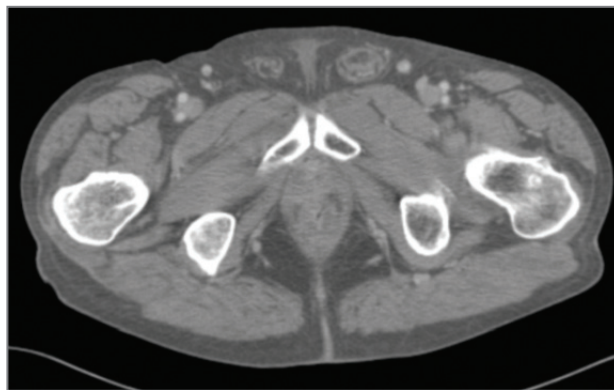
### Conclusion and CyberKnife® Advantages

Radiosurgical treatment with the CyberKnife System for perineal lesions near the rectal wall and urethra is not widely described in the literature and should be investigated thoroughly. This preliminary experience could be a first step towards creating a radiosurgical treatment choice in selected patients with this disease.

The acute tolerance and absence of any late toxicity observed here opens new perspectives in the treatment of pelvic lesions with radiosurgery. The use of the CyberKnife System allows a clinician to perform accurate treatment because of its capability to track the tumor throughout treatment.



*T2-weighted MRI, with marginal Gadolinium enhancement, acquired 8 months post-treatment. The lesion has completely disappeared and is substituted by a "lamellar streak" along the inferior profile of the cavernous urethra.*



*Contrast-enhanced CT scan acquired 18 months post-treatment showing no evidence of disease in the perineal region.*

### CYBERKNIFE AT SAN BORTOLO HOSPITAL

The CyberKnife System, installed in January 2003, was the first in Italy and Europe. By December 2005 it had been used to treat over 775 patients. The CyberKnife System allows the physicians to provide a targeted, painless alternative to open surgery and offers a treatment option for certain tumors that are otherwise untreatable. In 2005 more than 320 patients were treated (intracranial 74%, spine 3%, and extracranial non-CNS 23%).

#### References

1. Niehoff P, Loch T, Numberg N, Galalae R, Egberts J, Kohr P, Kovacs G Feasibility and preliminary outcome of salvage combined HDR brachytherapy and external beam radiotherapy (EBRT) for local recurrences after radical prostatectomy. *Brachytherapy*. 2005;4(2):141-5.
2. Beyer DC, Salvage brachytherapy after external-beam irradiation for prostate cancer. *Oncology (Williston Park)*. 2004 Feb;18(2):151-8; discussion 158-60, 163-4.

