

## PANCREATIC ADENOCARCINOMA



Georgetown  
University  
Hospital 

*MedStar Health*

Georgetown University Hospital CyberKnife® Team:

Medical Oncologist: John Marshall, M.D.

Radiation Oncologist: Gregory J. Gagnon, M.D.

Medical Physicists: Michael S. Lundsten, M.Sc.  
Sonja Dieterich, Ph.D.

Radiation Therapists: Sosena Asrat, R.T.(T.)  
Gerard Elie, R.T.(T.)

CyberKnife Center: Georgetown University Hospital  
Washington, DC

# PANCREATIC ADENOCARCINOMA

## DEMOGRAPHICS

Sex: Male  
Age: 54 years  
Histology: Unresectable, pancreatic adenocarcinoma

## CLINICAL HISTORY

Referred by: Self referral  
Previous Treatment: External beam radiation of 54 Gy in multiple fractions, plus chemotherapy

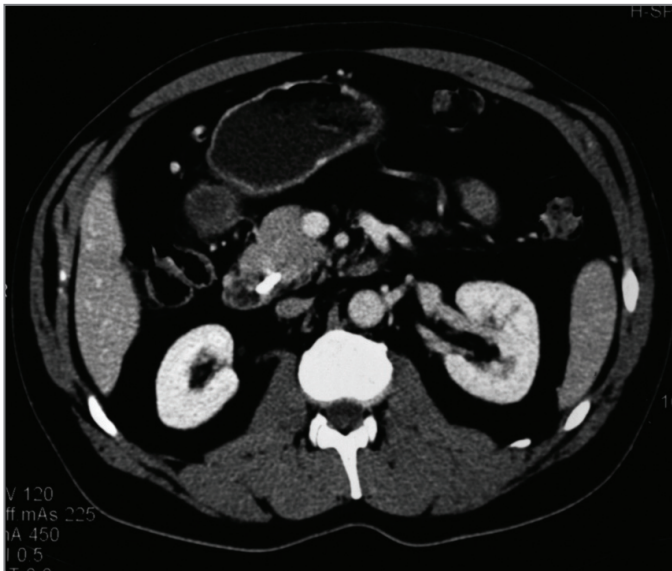
### Case History

The patient was in good health until he developed generalized pruritis and jaundice with a bilirubin level in the 5-7 mg/dl range. An elevated gastrointestinal cancer antigen (CA19-9) serum level of 189 units/ml was obtained. A CT scan with 3D reconstruction of the pancreas revealed a 2.5-cm mass AP within the uncinate process abutting the superior mesenteric artery (SMA) medially and the common bile duct (CBD) laterally. A 2 x 1 cm lymph node was identified within the portacaval space. An ultrasound-guided fine needle aspiration (FNA) revealed adenocarcinoma. A cholecystectomy was performed. Another 3D scan 3 days later revealed involvement of the superior mesenteric vein (SMV) with occlusive thrombus and tumor involving approximately 180 degrees of the SMA, although the vessel remained patent.

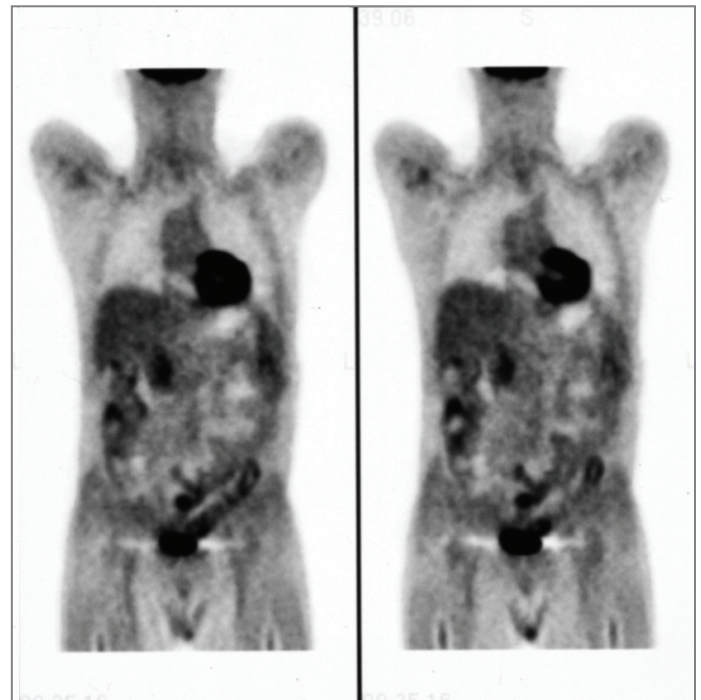
### CyberKnife® Treatment Rationale

The patient was not felt to be a resection candidate due to the involvement of the SMA and the SMV. He was treated with chemotherapy – continuous-infusion 5-FU, cisplatin (30 mg/m<sup>2</sup>) and interferon alpha throughout radiotherapy (see Previous Treatment, above). Radiotherapy was followed by postoperative chemotherapy – gemcitabine, Taxotere and Xeloda – which caused bone marrow suppression issues. Post-standard RT treatment, the pancreatic mass increased in size to 2.8 cm AP (compared to the previous 2.5 cm).

CyberKnife® radiosurgery was felt to be a reasonable treatment which might render the disease inactive or perhaps allow for subsequent surgery.



Pretreatment CT showing the pancreatic mass, which measured 2.5 cm AP. A biliary stent is seen in place. The tumor was deemed unresectable because of involvement of the SMA and SMV.



Pretreatment PET obtained on showing a positive FDG uptake in the pancreas.

TREATMENT DETAILS

Tumor Volume: 33.31 cc  
 Imaging Technique(s): CT  
 Rx Dose & Isodose: 24 Gy to 81%  
 Conformality Index: 1.56  
 Tumor Coverage: 97.2% of PTV  
 Number of Beams: 278

Fractions: 3  
 Path Template: 3 path 900\_1000 mm  
 Tracking Method: 6D fiducial tracking  
 Collimator(s): 15 mm

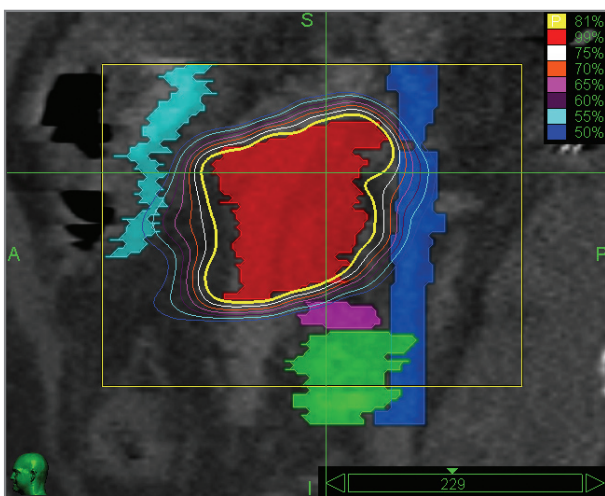
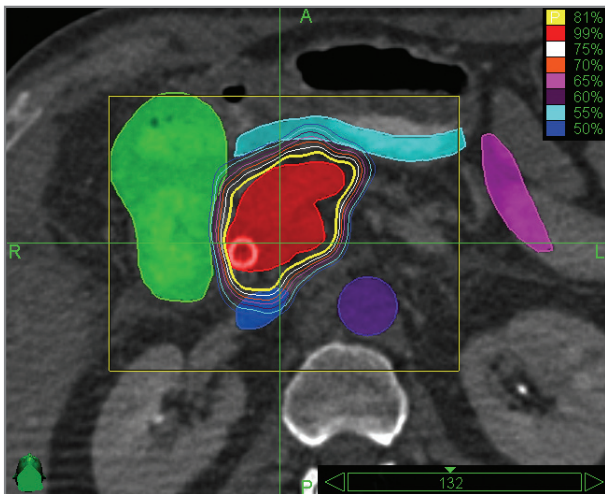
Planning Process and Goals

The 81% isodose line represents the prescribed dose of 24 Gy to the tumor. The treatment plan provided a 1.56 conformality index. Tumor coverage was 97.2% of the planning treatment volume. The tumor and the critical structures (duodenum, stomach, bowel, aorta and inferior vena cava (IVC)) were contoured for dose calculation purposes. An optimized inverse treatment plan was created such that the 81% isodose contour provided a conformal index of 1.56 while minimizing dose to the critical structures.

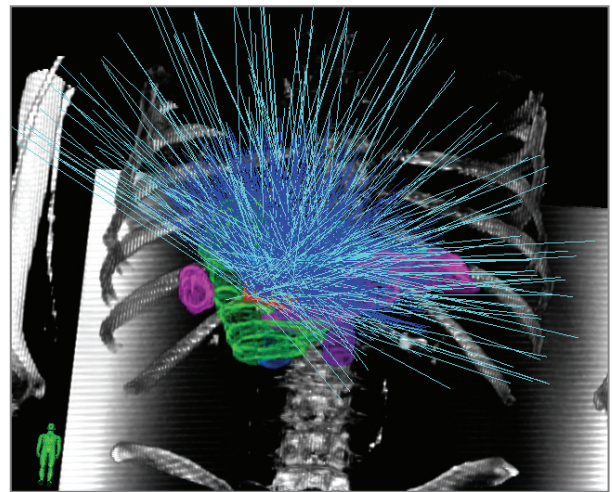
Treatment Delivery

The patient was treated with 24 Gy to the 81% isodose line in three daily fractions. This treatment was five months after completion of initial radiation therapy and chemotherapy and seven months after initial symptoms. The planning CT for the CyberKnife System revealed that the prior standard RT and chemotherapy had not reduced the size of the tumor, though the size appeared to have stabilized.

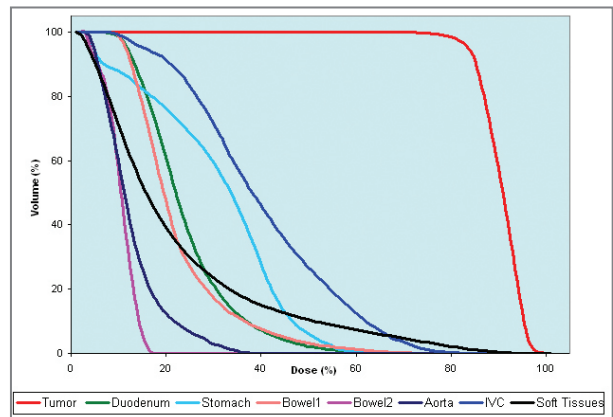
The patient tolerated his treatment with no morbidity other than some fatigue.



Axial and sagittal planning images with the tumor, isodose curves, and critical structures reconstructed from 1 mm sections. Note the highly conformal dose distribution to the pancreas avoids the aorta (violet), IVC (blue), duodenum (green), stomach (light blue) and bowel (pink and coral).



Rendering of the CyberKnife's beam positions for the treatment of the pancreas from an anterior view point.



Dose volume histogram (DVH) for tumor and critical structures.

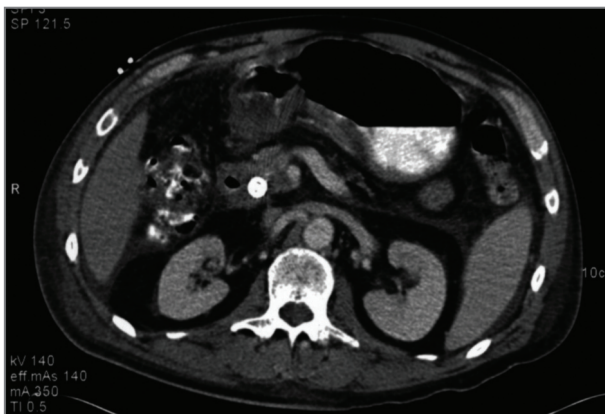
## PANCREATIC ADENOCARCINOMA

### Outcome and Follow-Up

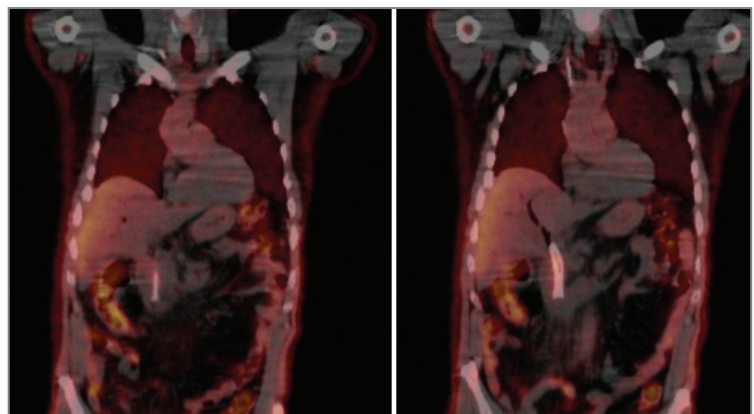
- Follow-up PET scan is negative in the pancreatic bed and the mass is not clearly identified
- Tumor demonstrated shrinkage on CT scan acquired 11 months post-CyberKnife® radiosurgery
- Patient has no pain, 13 months post-CyberKnife treatment, 22 months after initial symptoms
- Patient has survived beyond the 10 - 12 months commonly obtained for locally advanced disease<sup>3</sup>

### Conclusion and CyberKnife Advantages

- Pancreatic cancer presents many problems, including significant nutritional problems, chronic pain, difficulties with local control, frequent systemic metastases, especially to liver, intraperitoneal metastatic spread, and a dismal survival rate; an improvement in local control will be a necessary but not sufficient step to improve on the current therapeutic outcomes
- The CyberKnife is well-poised to improve the local control rates—this is accomplished with high doses per fraction delivered via a highly conformal approach<sup>1-5</sup>; improvements in systemic therapy are also necessary, which can easily be sequenced into the treatment as the CyberKnife treatment is of short duration
- Therapeutic expectations of this disease are largely palliative, but systemic improvements could lead to survival improvements
- CyberKnife radiosurgery alone may produce survival gain in a small number of patients as suggested by this case



CT 11 months post-radiosurgery shows reduction in the tumor size compared to both the initial CT (p. 2) and the planning CyberKnife CT (p. 3) scans. No tumor recurrence has been observed.



Follow-up FDG PET-CT scan 11 months post-radiosurgery is negative in the pancreatic bed. The mass has significantly reduced in size since the CyberKnife radiosurgical procedure.

### CYBERKNIFE AT GEORGETOWN UNIVERSITY HOSPITAL ([www.georgetownuniversityhospital.org](http://www.georgetownuniversityhospital.org))

Georgetown University Hospital's (GUH) CyberKnife Robotic Radiosurgery System, installed in 2002, was the first system on the East Coast. The Synchrony® Respiratory Tracking System was added in 2004 and Xsight® Spine Tracking in 2006. The CyberKnife System allows GUH physicians to provide a targeted, minimally invasive alternative to open surgery and a treatment option for certain tumors that are otherwise untreatable. GUH physicians and the Radiation Oncology Department have created a multi-disciplinary approach to provide their patients with the most comprehensive diagnosis and treatment possible. Over 400 patients were treated in 2006, with a clinical workload of 45% intracranial, 20% spine and 35% extracranial non-CNS.

#### References

1. Murphy MJ, Adler JR, Bodduluri M, Dooley J, Forster K, Hai J, Le Q, Luxton G, Martin DP, Poen J: Image-guided radiosurgery for the spine and pancreas. *Computer Aided Surgery* 5(4):278-88, 2000.
2. Murphy MJ, Martin D, Whyte R, Hai J, Ozhasoglu C, Le Q: The Effectiveness of Breath Holding to Stabilize Lung and Pancreas Tumors During Radiosurgery. *International Journal of Radiation Oncology Biology Physics* 53(2):475-482, 2000.
3. Koong AC, Le QT, Ho A, Fong B, Fisher G, Cho C, Ford J, Poen, J, Gibbs IC, Mehta VK, Kee S, Trueblood W, Yang G and Bastidas JA: Phase I Study of Stereotactic Radiosurgery in Patients with Locally Advanced Pancreatic Cancer, *Int. J. Radiation Oncology Bio. Phys.* 58(4):1017-1021, 2004.
4. Perman M, Bellairs EE, Wu X, Schwade, JG: Cancer of the pancreas with special reference to epidemiology & radiosurgery. In Mould RF et al. (eds.): *Robotic Radiosurgery*, Vol 1, Sunnvale, CA: CyberKnife Society Press, 2005.
5. Goodman KA, Koong AC: CyberKnife radiosurgery for pancreatic cancer. In Mould RF et al. (eds.): *Robotic Radiosurgery*, Vol 1, Sunnvale, CA: CyberKnife Society Press, 2005.

