

## BILATERAL TRIGEMINAL NEURALGIA

CENTRODIAGNOSTICOITALIANO



CyberKnife® Team:

Neurosurgeon: Marcello Marchetti, M.D.

Radiation Oncologist: Laura Fariselli, M.D.  
Ida Milanesi, M.D.  
Livia C. Bianchi, M.D.

Medical Physicist: Lorenzo Brait, Ph.D.

CyberKnife Center: Department of Neurosurgery,  
Division of Radiotherapy,  
Fondazione IRCCS Istituto Neurologico  
C. Besta, Milano, ItalyCyberKnife Center, Centro Diagnostico  
Italiano, Milano, Italy

## BILATERAL TRIGEMINAL NEURALGIA

### DEMOGRAPHICS

Sex: Female  
Age: 85 years  
Histology: Bilateral trigeminal neuralgia

### CLINICAL HISTORY

Referred by: Neurosurgeon  
Past Medical History: Bilateral cataract surgery, chronic sinusitis, bilateral knee prostheses, cerebello-pontine angle meningioma (stable since 1974)

### Case History

An 85-year-old woman presented with severe and disabling facial pain. The patient had been diagnosed 10 years prior with bilateral idiopathic trigeminal neuralgia. During her first visit to our center in late 2004 she described her pain as paroxysmal, electric shock-like, occurring along the distribution of the first branch of left trigeminal nerve and first and second branch of the right trigeminal nerve. The pain was triggered by tactile stimulation of the face. The patient had a Barrow Pain Intensity Score (BPS) of 4 and no facial numbness. The patient initially experienced a good response to medical treatment, but had since become increasingly resistant to medication.

Pre-treatment MRI showed possible neurovascular compression just into the cisternal portion of the left trigeminal nerve. No radiological evidence of neurovascular compression of the right trigeminal nerve was present. The MRI also documented a meningioma in the right cerebello-pontine angle. This meningioma proved to be radiologically stable by comparison to previous diagnostic images taken 30 years prior, and therefore no treatment was pursued for this lesion as it was felt this was not contributing to the patient's new current symptoms.

### CyberKnife® Treatment Rationale

CyberKnife Radiosurgery for trigeminal rhizotomy was considered the treatment of choice given this patient's increasing resistance to medication. In addition, the patient was considered to be a poor candidate for surgery due to her advanced age. The left trigeminal neuralgia was treated with the CyberKnife System in October 2004, and the right trigeminal neuralgia was treated in June 2006.

**TREATMENT DETAILS**

Target Site:	In both cases a 4-mm length of trigeminal nerve was treated	Number of Beams:	63 beams for left-side treatment; 64 for right side
Imaging Technique(s):	T1 Gadolinium MRI and a contrast-enhanced CT scan	Tracking Method:	Skull 6D tracking system
Fractions:	Single fraction per side	Collimator(s):	5 mm
Rx Dose & Isodose:	55 Gy to 100%	Path Template:	3 head path 800 mm

**Treatment Planning and Delivery**

The patient's bilateral trigeminal neuralgia was treated in two stages, beginning with the left trigeminal nerve. Treatment planning was based on a 1.25-mm slice T1 gadolinium MRI, including fast imaging employing steady-state acquisition (FIESTA), and a contrast-enhanced CT scan. The obtained images were fused to better define the intracisternal portion of the trigeminal nerve and optimize target definition. The target was defined as a segment of 4 mm of trigeminal nerve localized in the cisternal portion, 2 mm anterior to the dorsal root entry zone (see Figure 1, left panel). The prescribed dose was 55 Gy delivered to the 100% isodose line. The dose constraint to brainstem was 10 Gy, and the dose limit for the left 7th and 8th cranial nerves was 6.55 Gy (see Figure 2, left panel). The smallest collimator (5 mm) was used.

In June 2006 the patient underwent a second CyberKnife® radiosurgery treatment for the right trigeminal nerve. Treatment of the right nerve was similar to treatment of the left; the target was the 4 mm of trigeminal nerve in the cisternal portion 2 mm anterior to the dorsal root entry zone (see Figure 1, right panel), and 55 Gy was delivered to the 100% isodose line. The dose constraint to the brain stem was 11 Gy, and for the left 7th and 8th cranial nerves it was 8.2 Gy (see Figure 2, right panel).

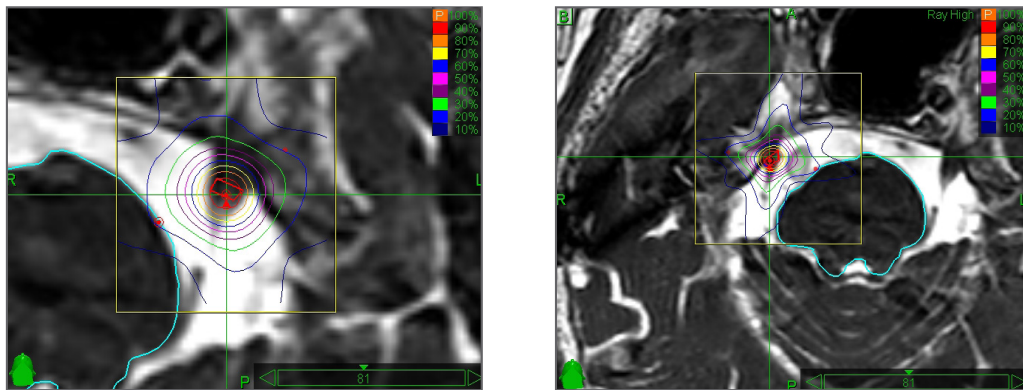


Figure 1. Plans for the left (left panel) and right (right panel) trigeminal nerve treatments. In both cases 55 Gy was delivered to the 100% isodose line (orange contour).

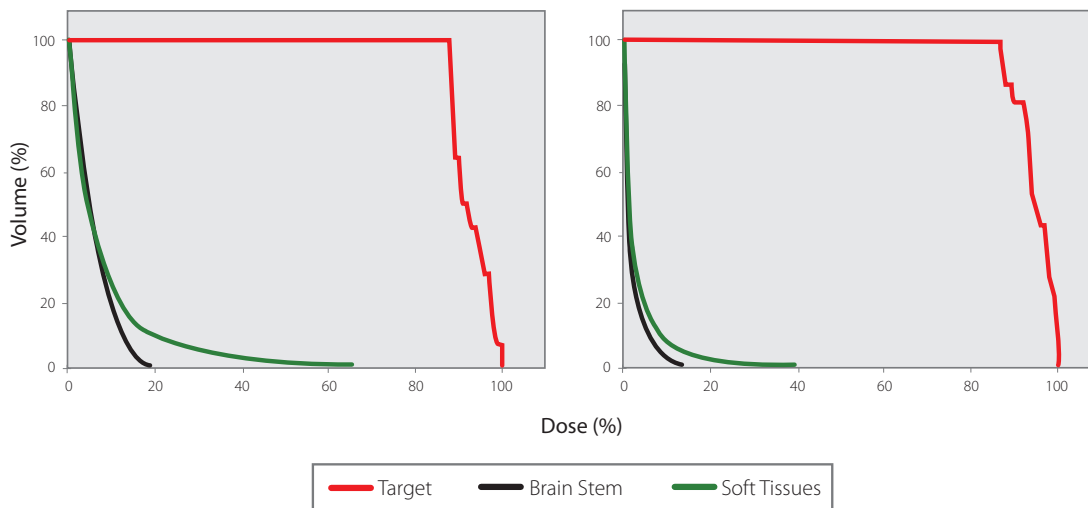


Figure 2. Dose-volume histograms for both plans. Note high dose to the nerve and sparing of brain stem and nearby soft tissue.

## BILATERAL TRIGEMINAL NEURALGIA

---

### Outcome and Follow-Up

#### LEFT TRIGEMINAL NERVE

- Thirty days after treatment the patient reported complete pain relief on the left side accompanied by mild dysesthesia (which resolved 4 months post-treatment after the patient accidentally fell down and suffered a mild hemorrhagic stroke, from which she recovered completely)
- The patient continued on medication during the year-and-a-half period between treatment of the left trigeminal nerve and treatment of the right trigeminal nerve

#### RIGHT TRIGEMINAL NERVE

- Twenty days after treatment the patient reported relief of pain to a BPS of 3; two months after treatment the patient reported complete resolution of the pain
- Since completing both treatments the patient has been pain-free and medication-free

### Conclusion and CyberKnife® Advantages

- CyberKnife® Stereotactic Radiosurgery is a safe and effective therapeutic modality for the treatment of medication-refractory trigeminal neuralgia
- Rapid and durable pain relief was achieved without the risks associated with open surgery or post-operative recovery

#### **CENTRO DIAGNOSTICO ITALIANO (CDI)**

Centro Diagnostico Italiano (CDI) is a private medical center established in 1975. The mission of CDI is to assure its leadership in healthcare by providing the widest range of preventive, diagnostic and therapeutic services while constantly researching ways to improve our patient care. CDI serves the Milanese territory by providing access to the CyberKnife via the CyberKnife Milan Project.

#### **FONDAZIONE ISTITUTO NEUROLOGICO CARLO BESTA**

The Fondazione Istituto Neurologico Carlo Besta is internationally recognized as a leading center for neuroscience. The Institute belongs to the Health Promoting Hospitals network, a project of the World Health Organization. The Istituto specializes in neurological disorders, surgical and oncological pathologies, and chronic and rare diseases. Its philosophy is to continually improve the efficacy of treatments by creating a synergy between scientific research and healthcare assistance.



**CyberKnife®**