

## MEDICALLY INOPERABLE PRIMARY LIVER CARCINOMA



Tianjin Medical University, Cancer Institute  
and Hospital CyberKnife® Team:

Radiation Oncologist: Zhiyong Yuan, M.D.

General Surgeon: Ming Gao, M.D.

CyberKnife Physicists: Yang Dong, Ph.D.  
Jingsheng Wang, Ph.D.

CyberKnife Center: Tianjin Medical University,  
Cancer Institute and Hospital  
Tianjin, China

## MEDICALLY INOPERABLE PRIMARY LIVER CARCINOMA

### DEMOGRAPHICS

Sex: Male  
Age: 65 years old  
Histology: Hepatocellular Carcinoma

### CLINICAL HISTORY

Referred by: General Surgeon  
Past Medical History: 20-year history of alcohol abuse

### Case History

A 65-year-old man with history of cirrhosis due to alcohol abuse was found to have a solitary lesion in the dome of his liver consistent with hepatocellular carcinoma (HCC). A PET-CT scan suggested hepatic dome carcinoma without evidence of extrahepatic disease. Biopsy by ultrasound-guided percutaneous needle puncture confirmed the diagnosis of HCC. The patient was also noted to have an elevated alpha-fetoprotein (AFP) level of 193.6 µg/L at that time. The patient's liver disease was classified as Child-Pugh class A, and the staging of the patient's HCC was T1N0M0.

The patient underwent transcatheter arterial chemoembolization (TACE). Despite two rounds of treatment with TACE over the next two months, AFP levels continued to increase to 619 µg/L. The patient was readmitted to the hospital and a PET-CT scan revealed a higher SUV uptake at the tumor site, highly suggestive of tumor progression.

### CyberKnife® Treatment Rationale

The patient was not a candidate for surgery due to his advanced level of cirrhosis. Furthermore, the patient had tumor recurrence after two lines of TACE; an additional TACE treatment was not a viable option. External beam radiation therapy was rejected for this patient because clinicians felt it would be difficult to meet dose-volume constraints with liver reserve compromised by cirrhosis. CyberKnife® treatment was chosen because it is a non-invasive, ablative treatment that offers excellent tumor control while minimizing damage to the cirrhotic liver and adjacent organs.

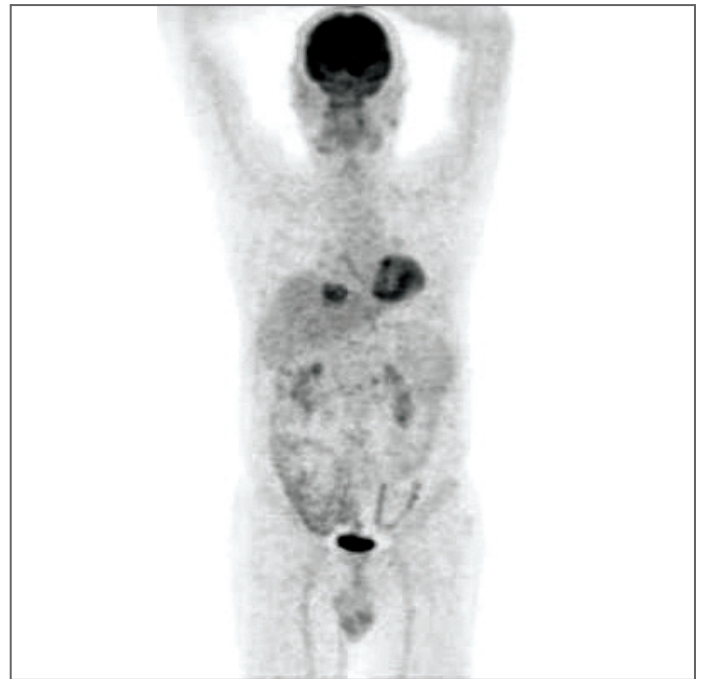


Figure 1. PET-CT scan demonstrates persistent high SUV uptake by the tumor despite two lines of transcatheter arterial chemoembolization.

# MEDICALLY INOPERABLE PRIMARY LIVER CARCINOMA

## TREATMENT DETAILS

Gross Tumor Volume (GTV): 35.8 cc  
 Tumor Diameter: 2.9 cm by 4.4 cm  
 Imaging Technique(s): CT (1.25 mm thickness) and PET-CT  
 Rx Dose & Isodose: 50 Gy to 75% isodose line  
 Fractions: Five fractions

Path Template: Body 900-1000  
 Number of Beams: 126 non-isocentric, non-coplanar beams  
 Tracking Method: Synchrony® System  
 Collimator: 35 mm

## Treatment Planning

The patient was prepared for treatment planning by implanting one fiducial within the tumor under ultrasound guidance. A CT scan (1.25 mm thickness) was obtained with the patient resting in a custom-fit vacuum cushion also used during treatment. PET-CT imaging was fused to the CT scan in the MultiPlan® planning system software. The hepatic tumor was contoured with a 3-mm expansion from the GTV to CTV and a 2-mm additional expansion from CTV to PTV. The normal liver, kidney, bowel, esophagus, stomach and spinal cord were contoured as critical structures; dose constraints for these structures are listed in Table 1.

## Treatment Delivery

The patient received 50 Gy to the 75% isodose line delivered in five equal fractions using 126 beams per fraction and a 35-mm collimator. Synchrony® fiducial tracking was used to track and correct for tumor motion during each fraction.

Critical Structure	Dose Constraints
Normal liver	50% limited to < 8 Gy
Kidneys	75% < 8 Gy
Bowel & stomach	50% < 8 Gy, Max dose < 20 Gy
Spinal cord	Max dose < 8 Gy

Table 1. Dose constraints to critical structures.

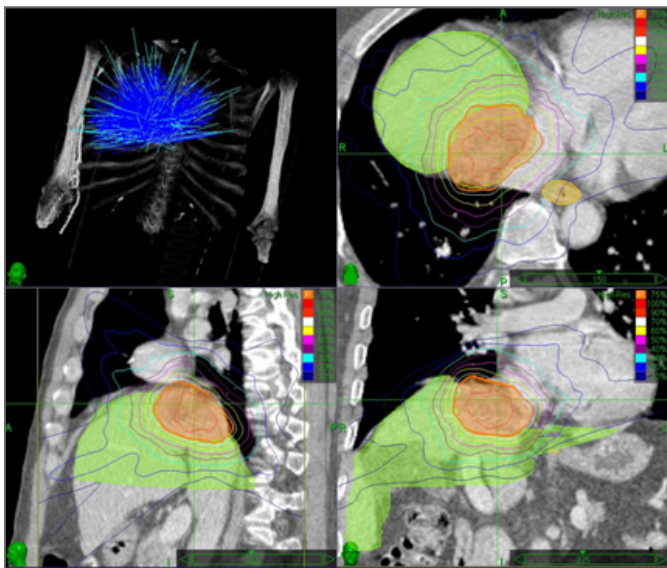


Figure 2. CyberKnife treatment. The patient received 50 Gy to the 75% isodose line delivered in five fractions using 126 beams per fraction.

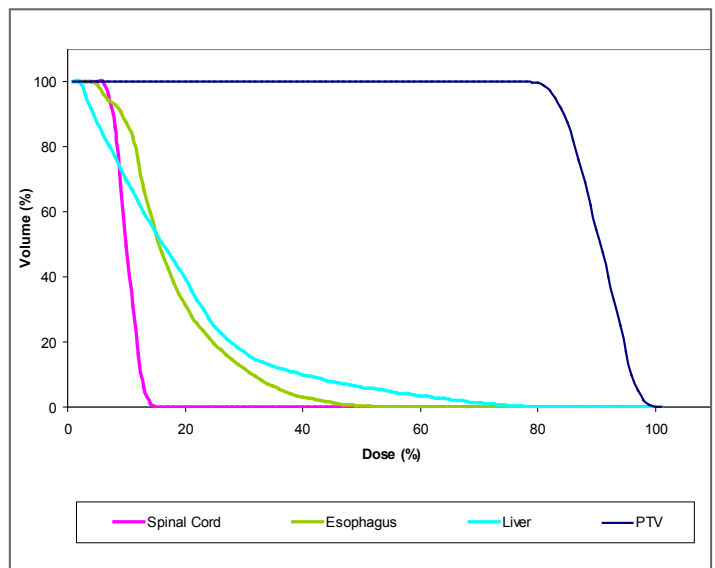


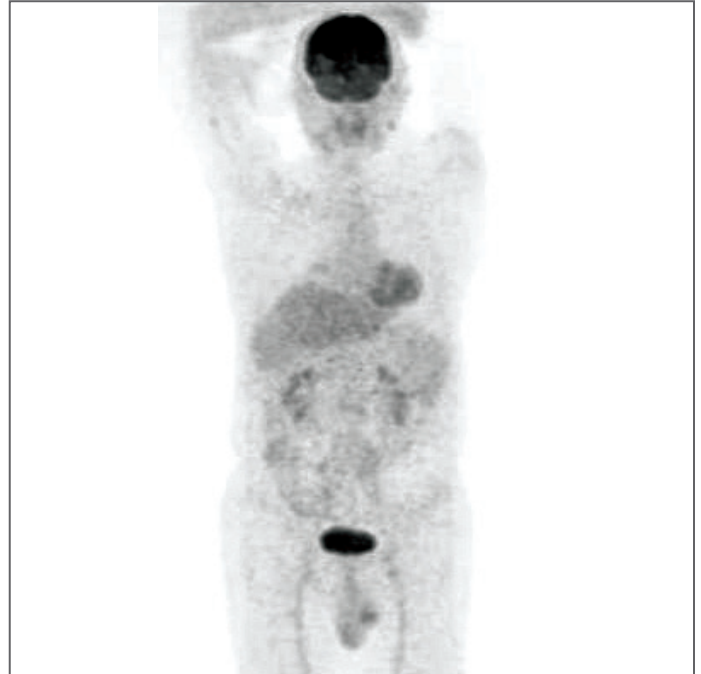
Figure 3. CyberKnife treatment. Dose-volume histogram shows the PTV and the rapid dose fall-off for normal liver, spinal cord and esophagus.

### Outcome and Follow-Up

- One month after treatment liver function tests remained stable as compared to pretreatment values; AFP remarkably decreased to 75 ug/L
- Two months after CyberKnife® treatment there was no visual evidence of the tumor on PET-CT nor was there any residual abnormal metabolic activity noted in the previous location of the tumor (Figure 4)
- Five and nine months after CyberKnife treatment PET-CT scans continued to demonstrate no evidence of disease; liver function continues to be stable

### Conclusion and CyberKnife® Advantages

- The patient tolerated the CyberKnife treatment well and no acute liver toxicity was noted
- After 9 months the tumor continued to be PET-CT negative and there were no noted side effects from the treatment



*Figure 4. Two months after CyberKnife treatment. PET-CT scan demonstrating no evidence of activity in the treated region of the liver tumor.*

### **TIANJIN MEDICAL UNIVERSITY CANCER INSTITUTE AND HOSPITAL**

CyberKnife Center, Tianjin Cancer Hospital is located in Tianjin City, China. Tianjin Cancer Hospital is considered the birthplace of Oncology in China. It has become one of the largest and most famous modernized cancer hospitals and is also one of the largest bases for cancer prevention, treatment, training and research in China. The center treats over 220,000 cancer patients a year, many of these patients with liver and lung cancer.

<http://www.tjmuch.com/english/>