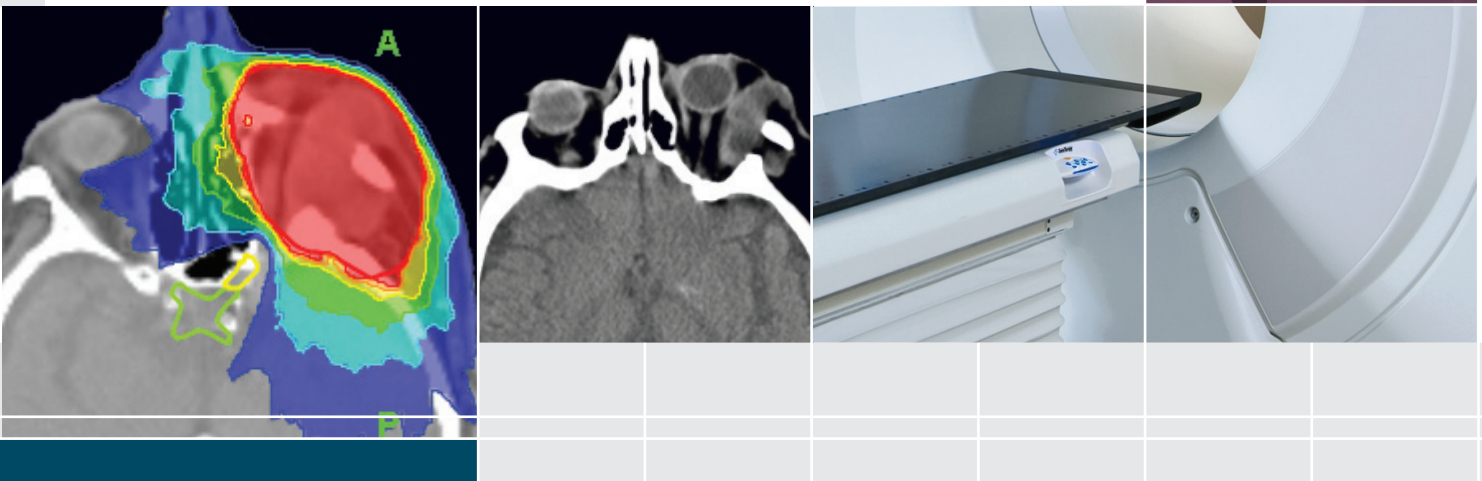


## Treating squamous cell carcinoma: Optic nerve and vision spared, quality of life restored

TomoTherapy  
HI-ART



**Institution:** University Hospital,  
Heidelberg, Germany

**Patient:** Male, 84 years

**Diagnosis:** Squamous cell carcinoma in upper  
jaw behind left eye

**Plan:** Primary target volume: Median 60 Gy  
Left optic nerve: Maximum~15 Gy  
Brain Stem: Maximum~15 Gy  
Optic chiasm: Maximum~15 Gy  
Ipsilateral optic lens:~20% at 5 Gy

**Treatment:** 30 fractions

Five years after recovering well from radiosurgery for a brain tumor, an 84-year-old patient began noticing pressure behind his left eye, which caused it to bulge. Soon he was experiencing double and then triple vision. When the vision got so bad that he could no longer work in the family orchard, the patient went to his physician. He was diagnosed with squamous cell carcinoma on his jaw, unrelated to the previous tumor.

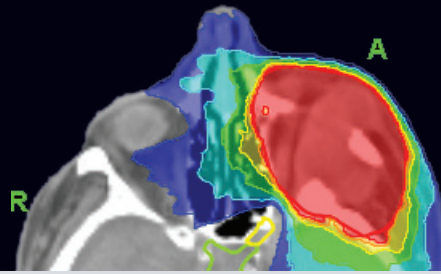
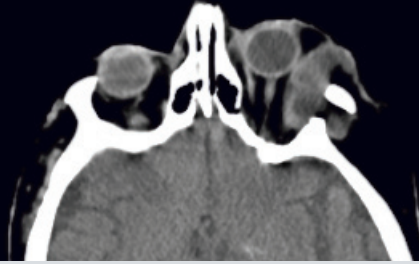
Using the precise Tomotherapy® Hi-Art® treatment system, the patient's radiation oncologist was able to spare the left optic nerve, which had already received the maximum allowable dose of radiation during treatment for the previous brain tumor. Within six months, the patient was tumor-free, his vision was fully restored and his eyeball no longer protruded. He was able to return to work in the orchard and celebrated his 85th birthday at home with family.

#### DEMOGRAPHICS

Sex: M  
Age: 84

#### CLINICAL HISTORY

Referred by: Primary Physician  
Histology: Early-stage squamous cell carcinoma  
Previous Treatment: Radiosurgery for unrelated brain tumor. Patient's left optic nerve had already received the maximum allowable dose of radiation.



Isodose

65

58

54

50

40

30

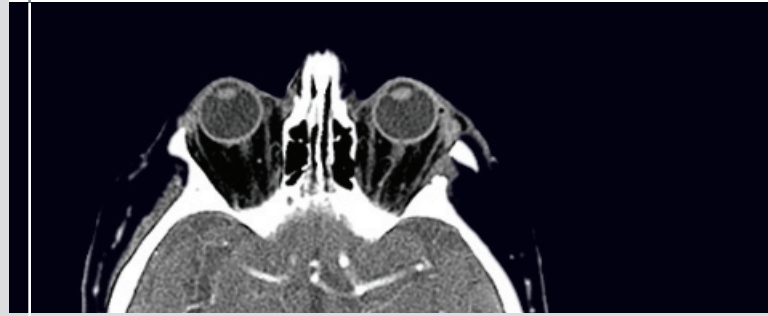
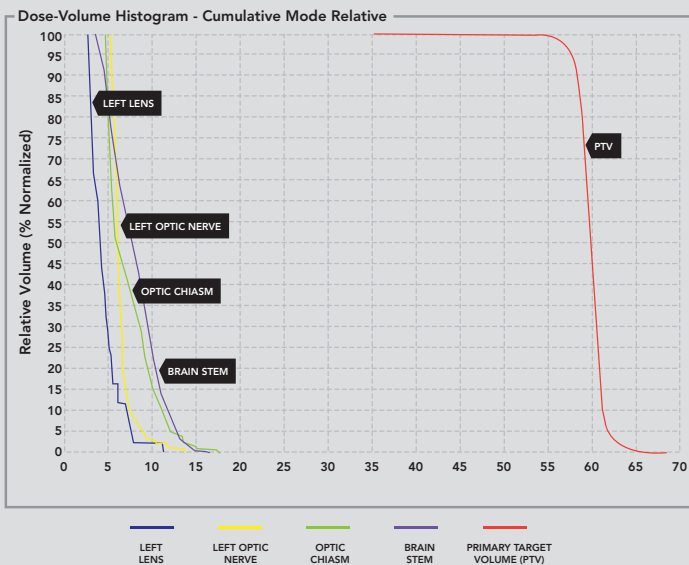
20

#### PATIENT HISTORY AND PRESENTATION

84-year-old male presented with a protruding left eyeball and intraocular pressure that impeded vision and kept him from overseeing the family business, a fruit orchard in the countryside of Dieburg, Germany.

The patient's physician diagnosed squamous cell carcinoma in the upper left jaw and recommended surgical removal of the jaw, eye and socket.

The patient and his family were concerned about surgery for two key reasons: 1) disfigurement and complete loss of sight in one eye could affect his quality of life and ability to continue working, and 2) the risks to the aging patient, who had undergone radiosurgery years earlier for an unrelated cavernous sinus meningioma, a type of brain tumor. The family requested options and were referred to Dr. Florian Sterzing, radiation oncologist at University Hospital in Heidelberg.



## TREATMENT PLAN AND DELIVERY

## OUTCOME

**Dr. Sterzing examined radiation options, but the case was complex because of the patient's previous treatment for an unrelated brain tumor years earlier.**

The patient's left optic nerve had already received the maximum allowable dose of radiation, so any new radiation therapy required precise delivery to spare the left optic nerve. The other complication was the protruding eyeball, which made conventional immobilization too painful. The only option was a soft head mask.

To accommodate the need for precision delivery, even when the patient couldn't be totally immobilized, Dr. Sterzing used the *TomoTherapy HiArt* treatment system.

The patient received a 30-fraction radiation treatment, as well as antibody treatment with Cetuximab to help increase therapy effectiveness by blocking receptors responsible for tumor growth.

While the patient had a skin reaction to the antibody infusions and experienced discomfort lying still for extended periods, he did not experience other side effects commonly associated with radiation therapy, such as nausea and dry mouth.

**Six months after radiation treatments, the tumor was gone. The patient's optic nerve and vision were spared, and the eyeball no longer protruded.**



[www accuray.com](http://www accuray.com)

© Copyright 2008 Accuray Incorporated. All Rights Reserved.  
The following words and logos as used herein are registered or common law trademarks or servicemarks of Accuray Incorporated in the United States and other countries: TomoTherapy; Reshaping Radiation Therapy; HiArt; TomoHD; CTrue; Every Patient, Every Day; and Tomo. All other trademarks are the property of their respective owners. TomoTherapy is a wholly owned subsidiary of Accuray Incorporated. M-CLN-024-1108