

POSTERIOR FOSSA RENAL CELL METASTASIS



NCH Regional Cancer Institute CyberKnife® Team:

Radiation Oncologist: Debra Freeman, M.D.

Surgeon: Paul D. Dernbach, M.D.

Medical Physicist: Mary Ellen Masterson-McGary, M.S.

Radiation Therapists: Lee Ann Perlman, R.T.(T.)
Kenny Shelton, R.T.(T.)
Lori Smith, R.T.(T.)

CyberKnife Center: NCH Regional Cancer Institute
Naples Community Hospital
Naples, FL

POSTERIOR FOSSA RENAL CELL METASTASIS

DEMOGRAPHICS

Sex: Female
Age: 65 years
Histology: L Posterior Fossa Renal Cell AC

CLINICAL HISTORY

Referred by: Neurosurgeon
Previous Treatment: 1) Right radical nephrectomy 18 years prior for localized renal cell carcinoma
2) Brain surgery for left frontal tumor and thoracotomy for lower lobe metastatic mass 6 months prior; both were histologically confirmed to be metastatic renal cell carcinoma

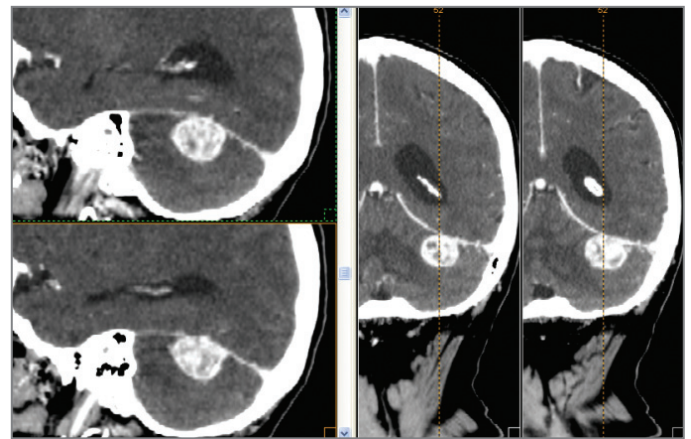
Case History

This female patient underwent a right radical nephrectomy for localized renal cell carcinoma. She had no adjuvant chemotherapy or radiation therapy based on an assessment of local disease. Eighteen years later, she developed mild ataxia with difficulty writing and golfing. A CT revealed a 1.3 cm high left parietal lobe enhancing lesion with surrounding edema. This tumor was surgically removed and was histologically confirmed to be metastatic renal cell carcinoma. Additional imaging revealed a right lower lobe lung mass of 3.5 x 2.0 cm. She underwent a thoracotomy and wedge resection of the right lower lobe; the mass had identical histologic features to the CNS lesion.

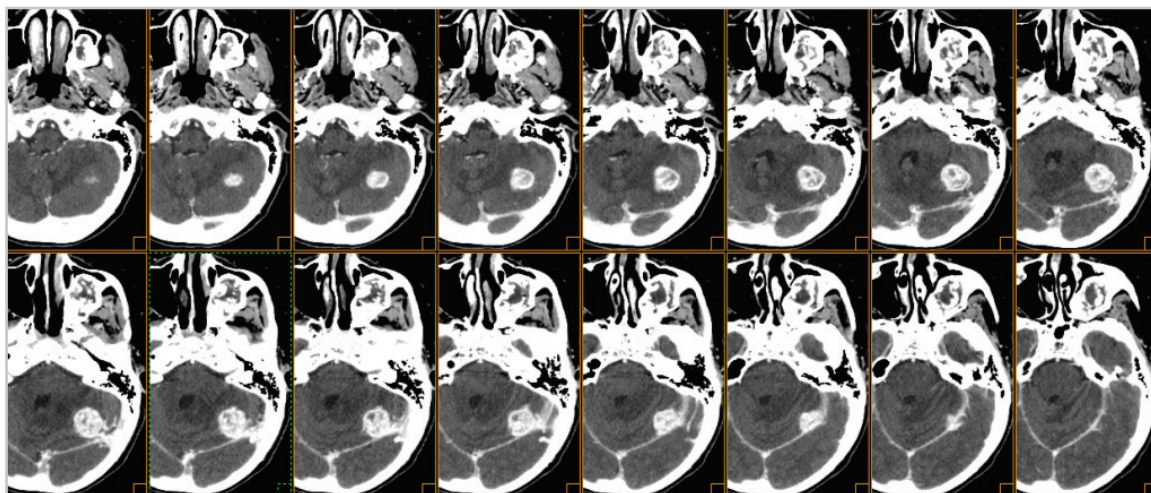
Post-surgery she was assessed by CT, whole-body PET and brain MRI. These imaging studies suggested no evidence of residual disease. Given the long disease-free interval between her initial nephrectomy and development of metastatic disease, the doubling time of her tumor was expected to be several years. Hence, observation was favored over radiation for her condition. Six months post-surgery, however, she developed mild ataxia and slight occipital headache. Follow-up MRI revealed a 2.5 x 2.0 x 1.5 cm enhancing mass in the left posterior fossa.

CyberKnife® Treatment Rationale

Due to the tumor location, stereotactic radiosurgery (SRS) was indicated in favor of operative surgery. The patient proactively inquired six months prior regarding the possibility of CyberKnife® treatment should she develop recurrent disease in the lung or brain. SRS is a well recognized technique for the treatment of cerebellar renal cell carcinoma metastases.^{1,2,3}



Sagittal and coronal CT reformatted images showing a solitary metastatic renal cell carcinoma in the posterior fossa (~ 2.5 cm diameter).



Sixteen consecutive 1.25 mm contrast-enhanced CT axial slices through the posterior fossa demonstrates volumetric extent of metastatic lesion.

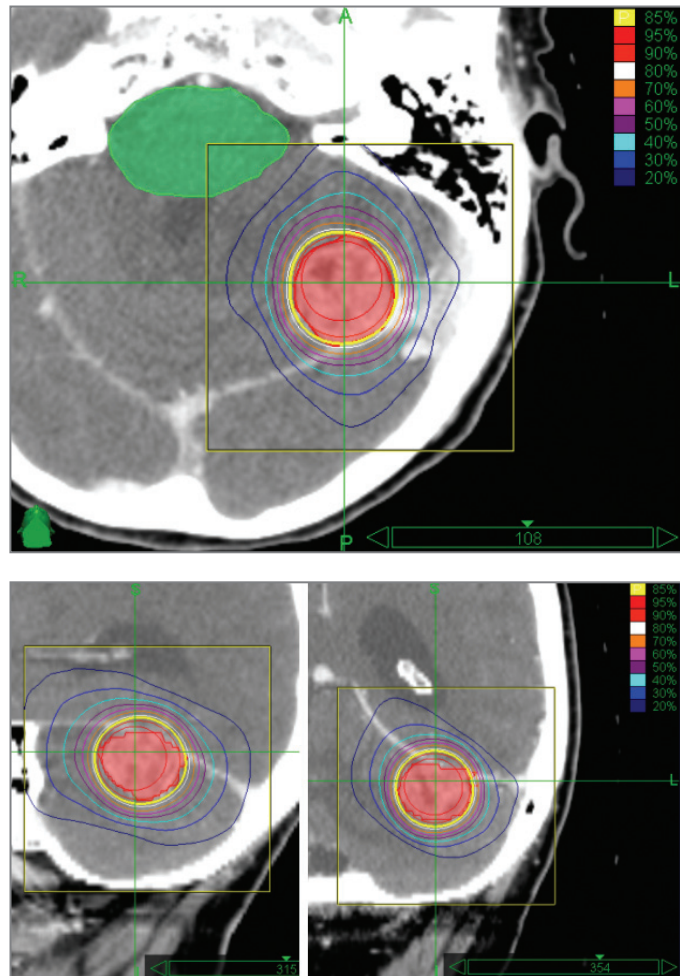
TREATMENT DETAILS

Tumor Volume: 4.99 cc
 Imaging Technique(s): CT, MRI
 Rx Dose & Isodose: 18 Gy to 85%
 Conformality Index: 1.36
 Tumor Coverage: 95.6% of PTV
 Number of Beams: 90

Fractions: 1
 Path Template: 3 path 800 mm
 Tracking Method: 6D Skull Tracking
 Collimator(s): 25 mm

Planning Process and Goals

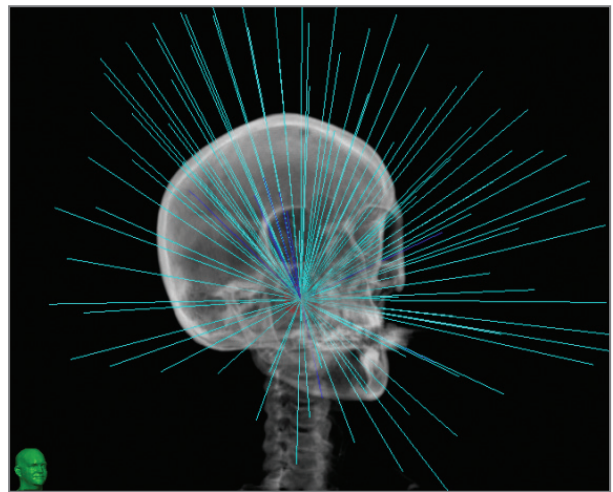
The tumor volume of 4.99 cc and the brainstem (critical structure) were contoured. The treatment plan was 18 Gy in one fraction prescribed to the 85% isodose line of the target volume, providing a 1.36 conformality index and a 1.18 homogeneity index.



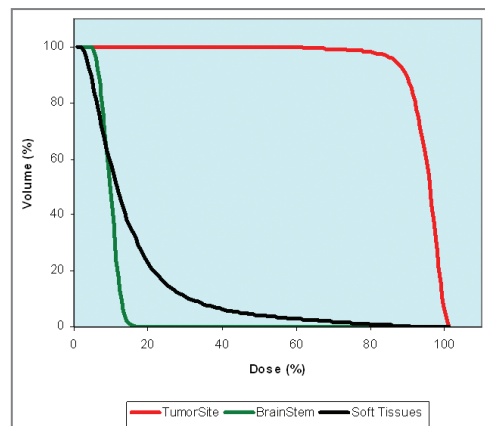
Axial, sagittal and coronal planning images (top to bottom right) showing the brainstem (green) as the critical structure. Note the isocentric treatment geometry and the highly conformal dose distribution.

Treatment Delivery

The treatment plan utilized 90 separately targeted beams using a 3 path 800 mm path set, the 6D automatic skull tracking technique and a 25 mm collimator using an isocentric treatment geometry. The maximum dose to the tumor site was 21.2 Gy. The maximum dose to the brainstem was constrained to be 3.86 Gy.



Right anterior oblique 3D image showing the 90 treatment beams and their relative intensities. These are centered at the single isocenter.



Dose-volume histogram showing tumor, critical structure and soft tissue doses.

Outcome and Follow-Up

The patient returned for weekly, then monthly, follow-up evaluations with excellent clinical results:

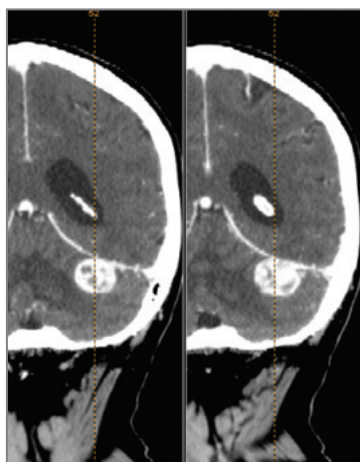
- One week post-SRS, occipital headaches and gait improved; at 3 weeks post-SRS, cerebellar function and gait returned to normal
- By ten weeks post-SRS patient was symptom-free; she continues to be symptom free 10 months post-treatment

Follow-up MRI scans were obtained 10 weeks and 4 months post-SRS with excellent results:

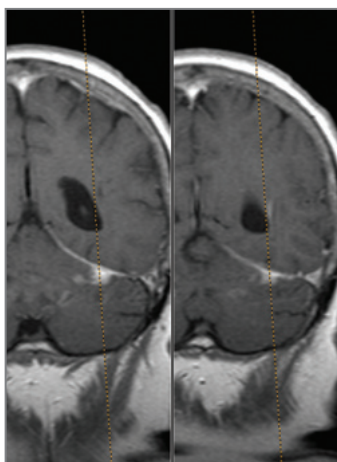
- Ten weeks post-SRS the original 2.5 cm lesion was markedly smaller (1.0 x 1.2 x 0.7 cm) with virtually no surrounding edema
- MRI obtained 6 weeks later demonstrated a complete resolution of the lesion

Conclusion and CyberKnife® Advantages

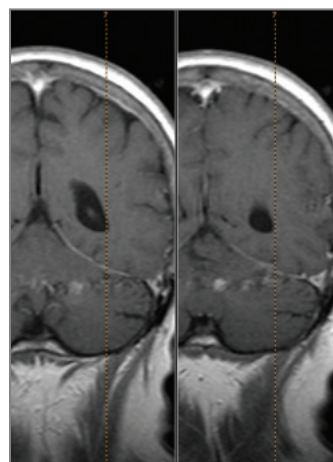
- The cerebellum is a relatively rare location for metastases of renal cell carcinoma¹
- The CyberKnife® System is a safe and effective frameless treatment for metastatic cell carcinoma in CNS structures^{2,3,4}
- The treatment was highly effective in resolving this tumor in a sensitive region of the brain; the only side effects were increased nausea immediately following treatment, which quickly resolved
- Though most CyberKnife treatment plans are non-isocentric, the CyberKnife System can perform isocentric treatment delivery similar to other SRS systems but without the invasive frame



Pretreatment CT: Showing the 2.5 cm ovoid tumor in the posterior fossa.



10 weeks Post-SRS: Lesion reduced to 18% of original size based on contrast-enhanced T1-weighted MRI.



4 months Post-SRS: Note the complete resolution of the lesion based on MRI.

NAPLES COMMUNITY HOSPITAL / NCH HEALTHCARE SYSTEM (www.nchmd.org)

The CyberKnife Radiosurgery System at Naples Community Hospital / NCH Healthcare System entered clinical service in the summer of 2004. Clinical use is currently 63% intracranial and 37% extracranial. The NCH Regional Cancer Institute (<http://cancer.nchmd.org/>), has a research affiliation with Duke University Health System, which provides access to some of the world's most promising clinical trials and cancer research. NCH Healthcare System and Duke University Health System work together to develop a comprehensive community cancer program. The Cancer Institute provides patients with quality care supported by state of the art technology such as the CyberKnife System.

References

1. American Cancer Society www.cancer.org/docroot/CRI/content/CRI_2_4_4X_How_is_kidney_cancer_treated_22.asp?nav=cri, site accessed 10/4/05.
2. Mori Y, Kondziolka D, Flickinger JC, et al. Stereotactic radiosurgery for brain metastasis from renal cell carcinoma. *Cancer* 83(2):344-53, Jul 1998.
3. Osama S. Abdelaziz, Stereotactic Radiosurgery for Malignant Intracranial Neoplasms: A Review and Critical Analysis of the Literature, *Journal of Radiosurgery*, 2(4):247 – 257, Dec 1999.
4. Gerszten PC, Ozhasoglu C, Burton SA, et al. CyberKnife frameless stereotactic radiosurgery for spinal lesions: clinical experience in 125 cases, *Neurosurgery* 55:89-99, 2004.

