

SPINAL
ARTERIOVENOUS
MALFORMATION



San Bartolo Hospital CyberKnife® Team:

- | | |
|----------------------|---|
| Neurosurgeons: | Frederico Colombo, M.D.
Leopoldo Casentini, M.D. |
| Medical Physicists: | Paolo Francescon, Ph.D.
Carlo Cavedon, Ph.D.
Stefania Cora, Ph.D.
Paolo Scalchi, Ph.D. |
| Biomedical Engineer: | Joseph Stancanello, Ph.D. |
| CyberKnife Center: | San Bartolo Hospital
Vicenza, Italy |

SPINAL ARTERIOVENOUS MALFORMATION

DEMOGRAPHICS

Sex: Male
Age: 37 years
Histology: T10-T11 Spinal AVM

CLINICAL HISTORY

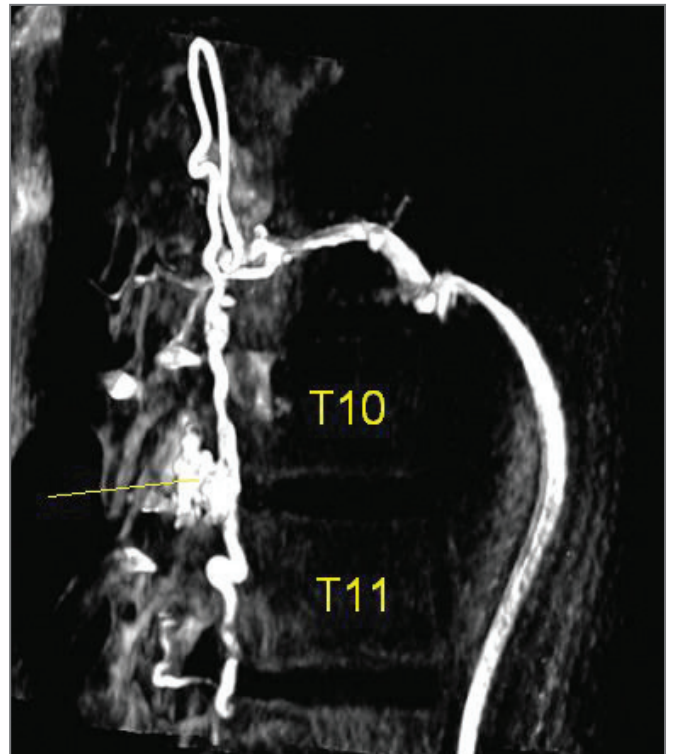
Referred by: Neurosurgeon
Past Medical History: None

Case History

This 37-year-old male presented with progressive paraparesis together with impaired bladder control and sexual function. A 0.8 cm³ spinal arteriovenous malformation (AVM) was diagnosed at the T10-T11 vertebral levels. Three attempts at embolization were made without success. The patient suffered two bleeding episodes, one as a complication following embolization. In each case, the patient's symptoms worsened leading to paraplegia and partial recovery in one case.

CyberKnife® Treatment Rationale

The patient was considered to be inoperable, and was referred by the neurosurgeon for radiosurgery using the CyberKnife® Robotic Radiosurgery System. Treatment of intracranial AVMs was one of the original radiosurgical applications, and radiosurgery has proven an effective modality in this field. Until recently, treatment of spinal AVMs has been impossible because of the limitations of rigid frame-based systems. By providing frameless stereotactic alignment, the CyberKnife System makes it possible to extend radiosurgery to extracranial targets, and its application to spine lesions has been previously reported.^{1,2,3} Patients are usually referred on the basis of unsuitability for conventional surgery, or when conventional surgery is refused, and in some cases (as in the present one) embolization will have been attempted prior to radiosurgery.



Pretreatment MR angiogram showing the nidus (arrow) and spinal vertebrae.

TREATMENT DETAILS

Tumor Volume: 0.8 cc
 Imaging Technique(s): CT, 3DRA, MR Angiography
 Rx Dose & Isodose: 18.2 Gy to 70%
 Conformality Index: 1.56
 Number of Beams: 130

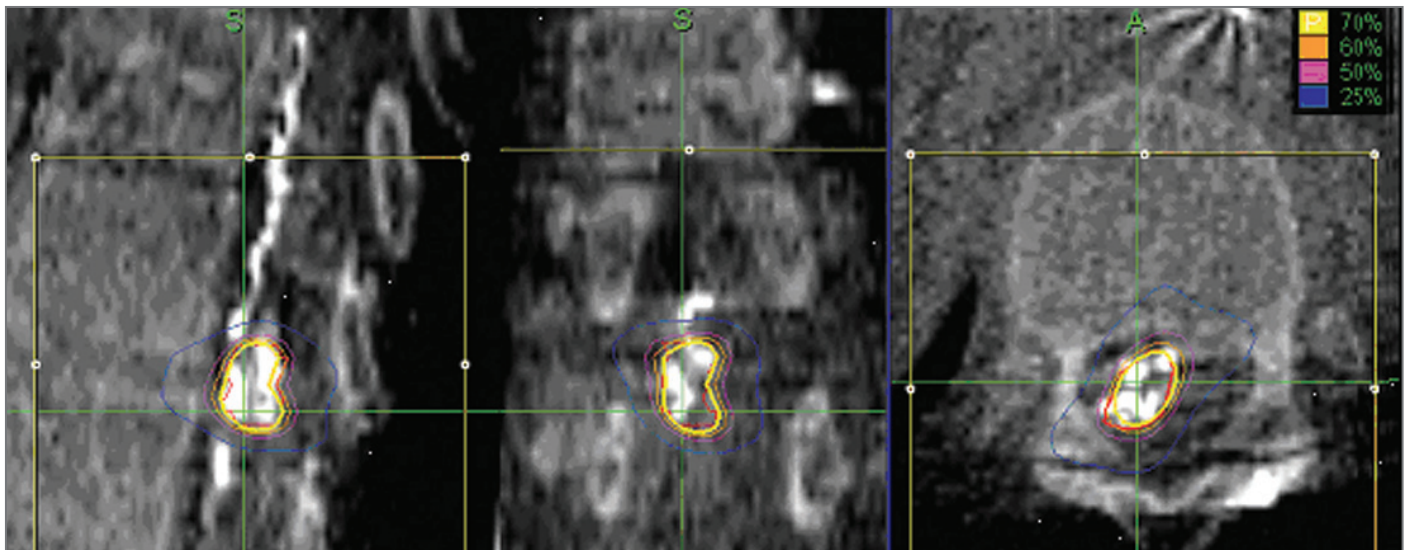
Fractions / Treatment Time: 4 / 40 minutes average
 Path Template: 3 path 900_1000 mm
 Tracking Method: Fiducial tracking
 Collimator(s): 5 mm

Treatment Planning and Delivery

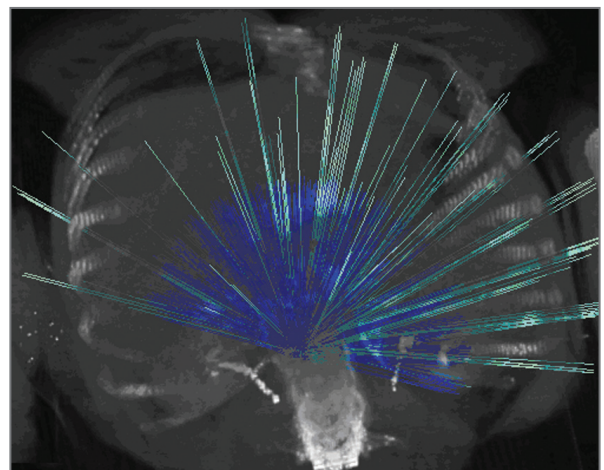
Four fiducials were implanted in the vertebral bodies above and below the nidus without complication. One week later pre-treatment images were acquired including 3D rotational angiography (3DRA), MR angiography, and contrast-enhanced CT scanning. These image-sets were registered using a normalized mutual information algorithm, and the target volume was defined using the 3DRA images. The patient was positioned

supine in a standard vacuum conformed immobilization

device. The supine position is preferred over prone because this minimizes the uncertainty due to respiratory motion. Inverse planning was used to generate a plan of 130 beams. A dose of 18.2 Gy was prescribed to the 70% isodose and delivered in 4 daily fractions using a 5-mm collimator. Fiducial tracking was used, and each outpatient session lasted 40 minutes including setup.



Isodose lines superimposed on multiplanar 3DRA fused images. Note contrast enhancement within the nidus.



3D reconstruction of the CT dataset showing the non-isocentric, non-coplanar beam arrangement.

SPINAL ARTERIOVENOUS MALFORMATION

Outcome and Follow-Up

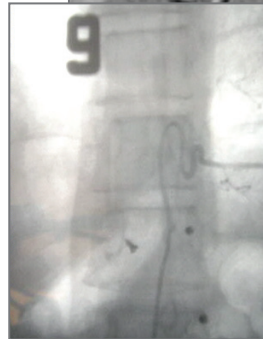
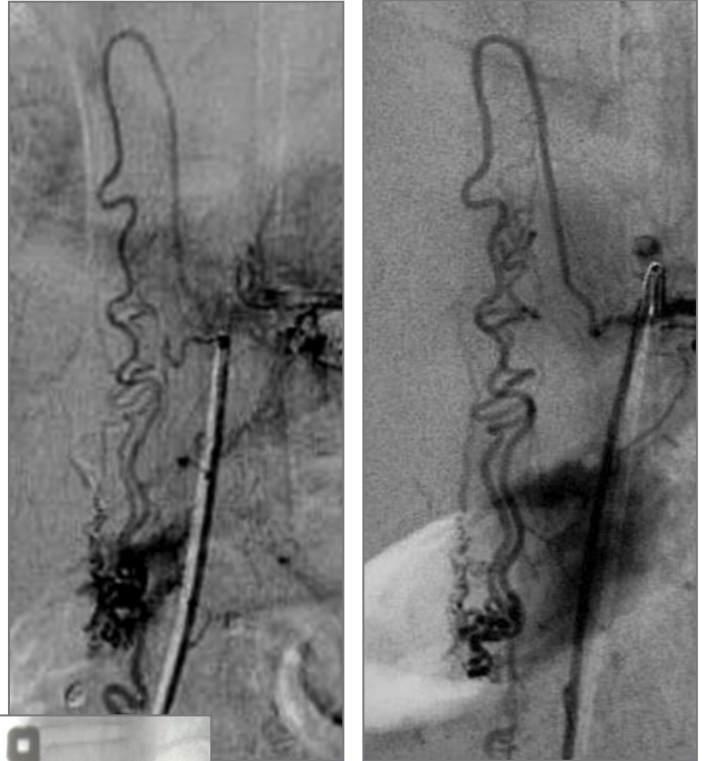
Follow-up MR angiography was performed at 6 and 12 months post-treatment. Progression of neurological symptoms was apparent for the first six months but then stabilized at 12 months post-treatment.

Twelve months post-treatment the AVM nidus volume had decreased in size. MR angiography was repeated at 24 months, and showed further reduction in the nidus volume. The patient has remained clinically stable with no bleeding episodes throughout this follow-up period, and there was no chronic treatment-related toxicity.

At 36 months MR angiography indicated complete obliteration and this was confirmed by selective digital subtraction angiography (DSA). The patient's symptoms had also improved with reappearance of normal knee reflexes and he can walk with a cane.

Conclusion and CyberKnife® Advantages

CyberKnife® radiosurgery was successfully applied to obliterate this intramedullary spinal AVM. 3DRA images were used to accurately define the AVM. Highly conformal dose delivery with steep falloff avoided radiation-induced neuropathy despite the location of the nidus within the spinal cord. The CyberKnife System allowed delivery of a non-invasive, painless treatment which resulted in hemorrhage-free follow-up period and ultimately in complete nidus obliteration within 36 months.



Angiographic images acquired pre-treatment (top left) and 24 months post-treatment (top right) showing significant nidus volume reduction. Complete nidus obliteration was achieved at 36 months (bottom left).

CYBERKNIFE AT SAN BORTOLO HOSPITAL

The CyberKnife System was installed in January 2003, and was the first installation in Europe. By March 2007 it has been used to treat nearly 1200 patients. Radiosurgery for AVMs had been performed in this center since 1984 using a conventional linear accelerator technique with a rigid head-frame⁴. Since 2003 these treatments have been transferred to the CyberKnife System. By March 2007 almost 220 intracranial and spinal AVMs have been treated using the CyberKnife System. Professor Colombo and his team have been pioneers in linac-based radiosurgery over 20 years. Their CyberKnife patient population is approximately 76% intracranial and 24% extracranial.

References

1. Ryu SI, Chang SD, Kim DH, Murphy MJ, Le QT, Martin DP, Adler JR Jr.: Image-guided hypo-fractionated stereotactic radiosurgery to spinal lesions. *Neurosurgery* 49(4):838-846, Oct 2001
2. Gerszten PC, Ozhasoglu C, Burton SA, Vogel WJ, Atkins BA, Kalnicki S, Welch WC: CyberKnife frameless stereotactic radiosurgery for spinal lesions: Clinical experience in 125 cases. *Neurosurgery* 55(1):89-98, Jul 2004
3. Stancanello J, Cavedon C, Francescon P, Cerveri P, Ferrigno G, Colombo F, Perini S: Development and validation of a CT-3D rotational angiography registration method for AVM radiosurgery. *Medical Physics* 31(6):1363-1371, June 2004
4. Colombo F, Benedetti A, Pozza F, Zanardo A, Avanzo RC, Chiarego G, Marchetti C: Stereotactic radiosurgery utilizing a linear accelerator. *Appl Neurophysiol* 48:133-145, 1985



CyberKnife®