

## NON-INVASIVE STEREOTACTIC RADIOSURGICAL TREATMENT OF NON-SMALL CELL LUNG CANCER

---



CyberKnife® Team:

Radiation Oncologist: Hoke Han, M.D.

Thoracic Surgeon: Mark Block, M.D.

Physicists: Alberto de la Zerda, Ph.D.  
Elizabeth Bossart, Ph.D.

Dosimetrist: Vidya Persaud

Therapists: April Hildebrand  
Steve Reyes

CyberKnife Center: CyberKnife Center of Miami

# NON-INVASIVE STEREOTACTIC RADIOSURGICAL TREATMENT OF NON-SMALL CELL LUNG CANCER

## DEMOGRAPHICS

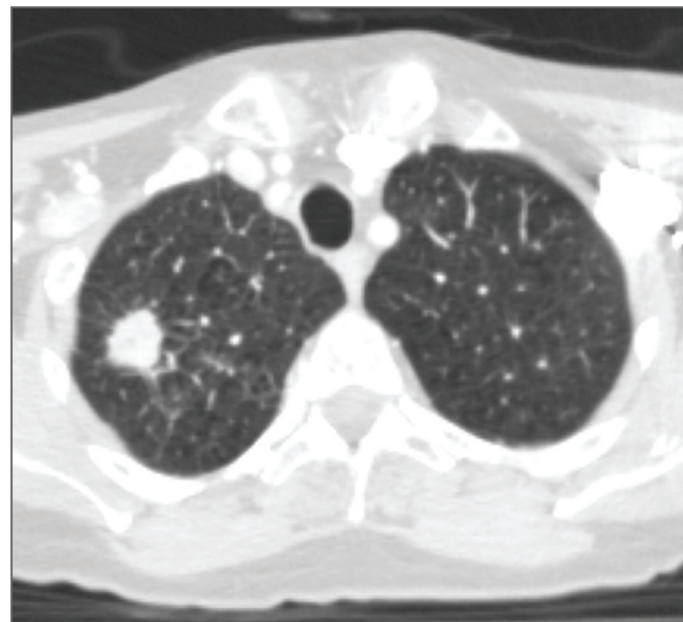
Sex: Female  
Age: 72 years  
Histology: Adenocarcinoma

## CLINICAL HISTORY

Referred by: Thoracic Surgeon  
Past Medical History: Smoker (50 pack-year history), COPD (chronic obstructive pulmonary disease), breast cancer, hypercholesterolemia

## Case History

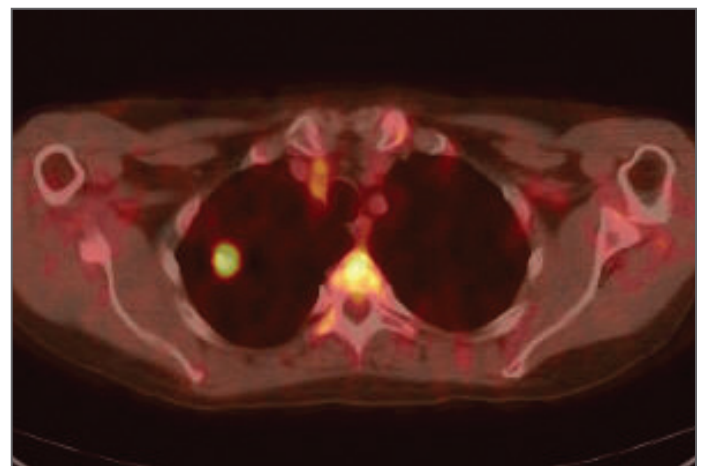
A 72-year-old female former smoker with a history of COPD presented for evaluation of a growing, PET-positive right upper lobe (RUL) lung lesion. The lesion was first discovered four years earlier when she had a chest CT for unclear reasons. At that time it measured 1 cm in diameter and reportedly was not active on PET. No intervention was recommended. No further imaging was performed until she presented with worsening shortness of breath and a cough. Repeat chest CT demonstrated that the lesion had grown, and now measured 1.5 x 1.2 cm. PET-CT two months later identified activity in the lesion with an SUV of 4.9. Biopsy results demonstrated the lesion to be consistent with NSCLC. Given the PET-CT and biopsy results, this patient was diagnosed with Stage 1a non-small cell lung cancer (T1N0M0 NSCLC).



Pre-treatment diagnostic CT axial image demonstrating 1.8 cm x 1.6 cm x 1.7 cm lesion in the upper lobe of the right lung.

## CyberKnife® Treatment Rationale

When possible, Stage Ia NSCLC is treated by primary surgical resection (lobectomy or segmentectomy).<sup>1,2</sup> Conventional radiation therapy and chemotherapy have been reserved for patients who refuse surgery or who are deemed medically inoperable because of associated co-morbidities. In recent years improved tumor control with relatively few complications has been achieved using high-dose, hypofractionated stereotactic radiation delivery.<sup>3-8</sup> The patient investigated several treatment options for the RUL lesion. Her pulmonary function tests (PFTs) showed a V02 max of 18 ml/kg/min, an FEV1 of 0.85 L (43% of predicted) and a perfusion scan demonstrated the contribution of the right lung to total lung function to be high (65%). Therefore, despite a good V02 max value, clinicians recommended against a lobectomy and recommended the CyberKnife® System as a treatment alternative. Repeat CT at this time showed the lesion to have increased in size to 1.8 x 1.8 cm. Given the relatively poor outcomes associated with conventional radiation therapy,<sup>9</sup> the inclusion of large volumes of normal lung tissue within the radiation field, and the patient's prior history of external beam radiation to the right breast for treatment of her breast cancer in the past, radiosurgery using the fiducial-free Xsight® Lung Tumor Tracking System was chosen to deliver focal, high-dose, hypofractionated radiation treatment that maximized dose to this patient's lung tumor and minimized dose to surrounding normal tissue. The non-invasive nature of this treatment allows patients to breathe freely as the CyberKnife System tracks tumor motion throughout treatment without the need for implantation of metal fiducials or other markers near the lung tumor.



Pre-treatment diagnostic PET-CT axial image demonstrating increased SUV uptake in the right upper lobe lesion.

# NON-INVASIVE STEREOTACTIC RADIOSURGICAL TREATMENT OF NON-SMALL CELL LUNG CANCER

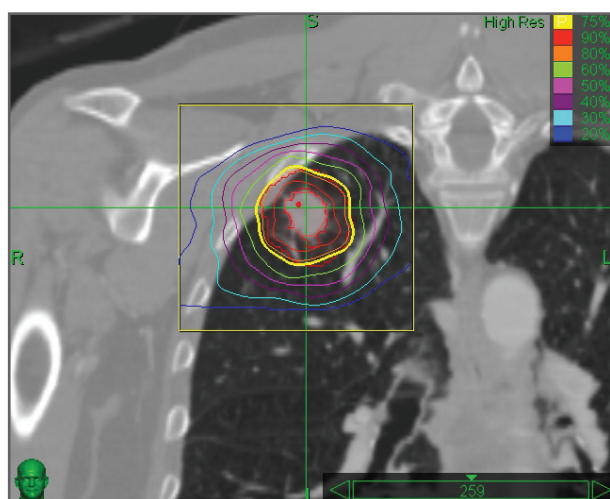
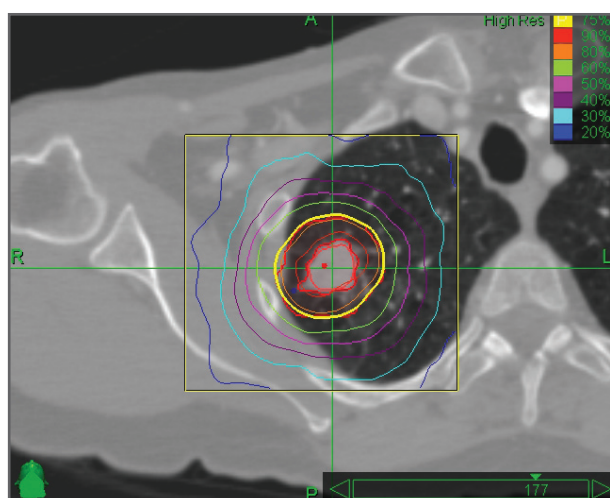
## TREATMENT DETAILS

Gross Tumor Volume (GTV): 3.60 cm<sup>3</sup>  
Imaging Technique(s): CT, PET-CT  
Rx Dose & Isodose: 60 Gy to 75%  
Conformality Index (PTV): 1.15  
Number of Beams: 148 beams/fraction  
Homogeneity Index: 1.33

Number of Fractions: 3 fractions of 20 Gy  
Tracking Method: Synchrony® with Xsight® Lung (No fiducials)  
Collimator(s): 20 and 30 mm  
Tumor Coverage: 100%

## Planning Process

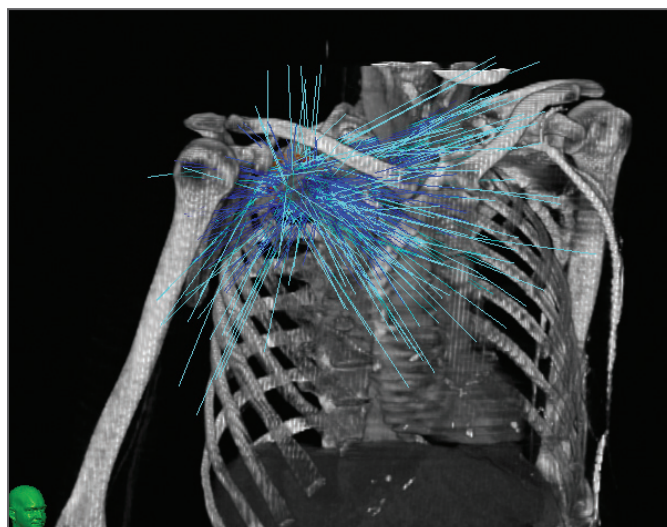
The patient's only preparation for treatment was a planning CT scan to identify the tumor target. Implantation of fiducial markers was not required given the use of the Xsight® Lung technology. Following completion of imaging, the lesion was outlined on the scans resulting in a gross tumor volume of 3.60 cm<sup>3</sup>. A treatment plan was created to deliver 60 Gy in 3 fractions to the 75% isodose line with 8-mm tumor margins to encompass microscopic extension and targeting uncertainties, using the 20-mm and 30-mm collimators.



Axial and coronal treatment planning images showing gross tumor volume (GTV, red) and planning tumor volume (PTV, red). The 75% prescription isodose line is shown in yellow.

## Treatment Delivery

The patient underwent CyberKnife® treatment using 148 beams/fraction. The prescribed dose covered 100% of the tumor volume with a homogeneity index of 1.33 and a conformality index of 1.15 for the PTV. The patient tolerated the procedure well.



Three-dimensional reconstruction of beam geometries.

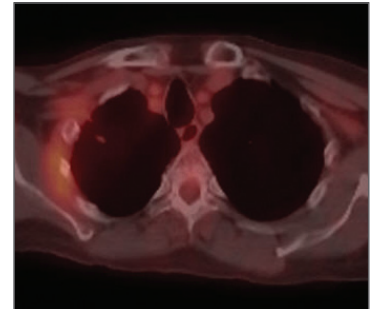
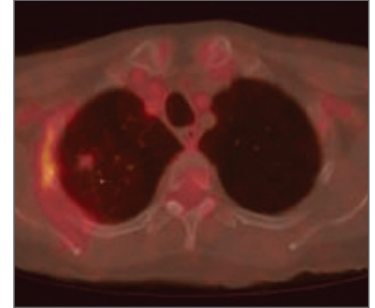
# NON-INVASIVE STEREOTACTIC RADIOSURGICAL TREATMENT OF NON-SMALL CELL LUNG CANCER

## Outcome and Follow-Up

- Four months after CyberKnife® treatment PET-CT imaging revealed an interval decrease in the size of the RUL lesion to less than 1 cm in maximum dimension (0.9 x 0.8 x 0.9 mm); there were no noted acute complications - the patient remained asymptomatic with stable post-treatment PFTs
- Eleven months after CyberKnife treatment PET-CT imaging demonstrated no evidence of disease with only residual scarring noted and no PET positivity; the patient continued to do well without any noted complications

## Conclusion and CyberKnife Advantages

- This patient had an excellent initial outcome with the CyberKnife System using Xsight® Lung Tracking; the patient was able to undergo treatment completely non-invasively without implanted fiducials or markers
- The Xsight Lung Tracking system allows the CyberKnife to track tumor motion continuously throughout treatment, minimizing irradiation of surrounding tissue and maximizing dose to the tumor, thus decreasing the risk of complications such as radiation pneumonitis
- No acute side effects or change in post-treatment PFTs were noted; at eleven months post-treatment there was no evidence of disease - patient continued to be without complications
- The CyberKnife System provides a completely non-invasive treatment option for selected patients with lung tumors who are poor surgical candidates because of associated medical conditions which make them unable to tolerate any degree of invasiveness in the treatment of their cancer



## CYBERKNIFE CENTER OF MIAMI

The CyberKnife Center of Miami, operational since 2003, was the first CyberKnife center on the South-East coast. The center was among the first to implement Xsight Spine and Xsight Lung tracking modalities. Over 700 patients with a wide range of clinical indications in various anatomical locations have been treated successfully. Much of the center's clinical and research work has been published, including several papers and chapters on lung radiosurgery.<sup>6-8,10-11</sup>

## References

1. Handy JR, Jr., Asaph JW, Skokan L, et al. What happens to patients undergoing lung cancer surgery? Outcomes and quality of life before and after surgery. *Chest* 2002;122:21-30.
2. Jones DR, Detterbeck FC. Surgery for stage I nonsmall cell lung cancer. In: Detterbeck FC, Rivera MP, Socinski MA, et al., editors. *Diagnosis and treatment of lung cancer: An evidence-based guide for the practicing clinician*. Philadelphia: W.B. Saunders; 2001. pp. 177-190.
3. McGarry RC, Papiez L, Williams M, et al. Stereotactic body radiation therapy of early-stage non-small-cell lung carcinoma: phase I study. *Int J Radiat Oncol Biol Phys* 2005;63:1010-1015.
4. Onishi H, Araki T, Shirato H, et al. Stereotactic hypofractionated high-dose irradiation for stage I nonsmall cell lung carcinoma: clinical outcomes in 245 subjects in a Japanese multiinstitutional study. *Cancer* 2004;101:1623-1631.
5. Timmerman R, McGarry R, Yiannoutsos C, et al. Excessive toxicity when treating central tumors in a phase II study of stereotactic body radiation therapy for medically inoperable early-stage lung cancer. *J Clin Oncol* 2006;24:4833-4839.
6. Brown WT, Wu X, Amendola B, et al. Treatment of early non-small cell lung cancer, Stage IA, by image-guided robotic stereotactic radioablation - Cyberknife. *The Cancer Journal* 2007; 13(2):87-94.
7. Brown WT, Wu X, Fayad F, et al. CyberKnife® Radiosurgery for Stage I Lung Cancer: Results at 36 Months. *Clinical Lung Cancer* 2007; 8(8): 488-492.
8. Brown WT, Wu X, Wen BC, et al. Early results of CyberKnife image guided robotic stereotactic radiosurgery for treatment of lung tumors. *Computer Aided Surgery*. Sept 2007;12(5):1-9.
9. Timmerman, R.D., Abdulrahman, R., Kavanagh, B.D., & Meyer, J.L. Lung cancer: A model for implementing stereotactic body radiation therapy into practice. *Front Radiat Ther Oncol.*, 2007; 40: 368-385.
10. Wu X, Fu D, De la Zerda A, et al. Patient Alignment and Target Tracking in Radiosurgery of Soft-Tissue Tumors Using Combined Fiducial and Skeletal Structures Tracking Techniques. *Robotic Radiosurgery Volume II: CyberKnife Society Press*; 2007; 31-36.
11. Brown WT, Perman M, Wu X, et al. Image-guided robotic stereotactic radiosurgery for treatment of lung tumors. In: Mould RF, Buchholz RD, Gagnon GJ, et al., editors. *Robotic Radiosurgery. Vol 1*. Sunnyvale, CA: CyberKnife Society Press; 2005. pp. 255-269.
12. Brown WT, Wu X, Amendola B, et al. Initial experience treating lung tumors with the CyberKnife. In: Urschel HC, Kresl JJ, Luketich JD, et al., editors. *Robotic Radiosurgery. Vol II. Treating Tumors that Move with Respiration*; 2007. pp. 155-163.



CyberKnife®