

PARTIAL BREAST IRRADIATION AFTER LUMPECTOMY



Swedish Radiosurgery Center at Swedish Medical Center
Seattle, Washington

CyberKnife® Team
Sandra Vermeulen, M.D.
Cristian Cotrutz, Ph.D.

PARTIAL BREAST IRRADIATION AFTER LUMPECTOMY

DEMOGRAPHICS

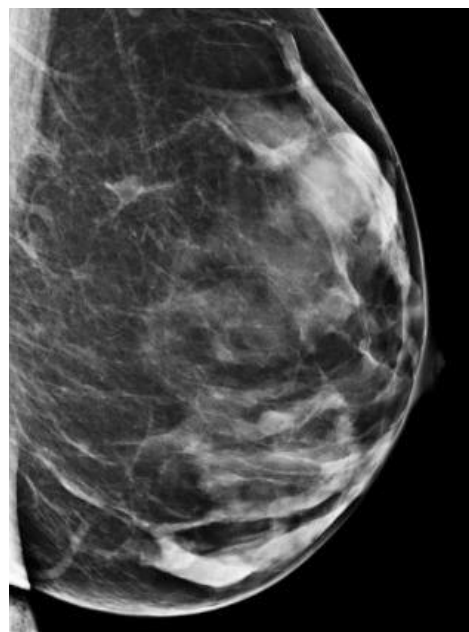
Sex:	Female
Age:	44 years old
Histology:	Infiltrating ductal carcinoma (IDC)
Past Medical History:	Breast cysts, Graves disease
	No prior surgeries
	Never pregnant

CLINICAL HISTORY

Family History:	Unspecified cancers on mother's side, breast cancer on father's side. Patient is of Ashkenasi Jewish heritage.
Pathologic Stage:	T1bN0Mx infiltrating ductal carcinoma and ductal carcinoma <i>in situ</i> (DCIS).

Case History

A 44-year-old woman presented with a density in the upper outer quadrant of her left breast detected on screening mammogram. An MRI confirmed this lesion to be the only suspicious mass in either breast. An ultrasound-guided core biopsy was consistent with an infiltrating ductal carcinoma. The patient underwent a lumpectomy and left axillary sentinel node dissection. Final pathology revealed a 0.8 cm, high-grade tumor with a Bloom-Richardson score of 8/9. No vascular/lymphatic space invasion was identified. DCIS of high nuclear grade without necrosis, estimated size of 0.8 cm, was present. Surgical margins were free of both invasive and noninvasive disease components. The infiltrating tumor was ER/PR negative and HER2/Neu 2+, as well as FISH positive for low level gene amplification. There was no evidence of metastasis in the dissected sentinel lymph nodes. The patient's postoperative course was uneventful.

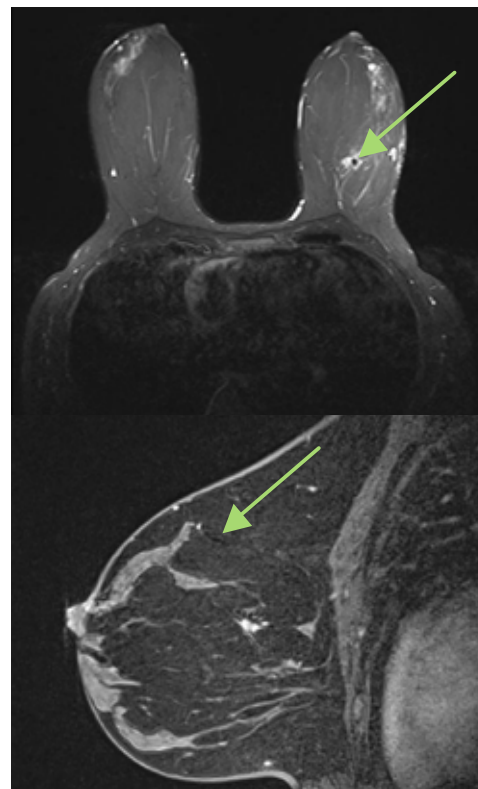


Screening mammography revealed new density in the outer upper quadrant of the left breast.

CyberKnife® Treatment Rationale

After surgery, the patient was seen in the Radiation Oncology Clinic. She was informed about the current standard of care, which includes about 6 weeks of daily radiation to the involved breast, as well as the accepted risks of side effects. At the time, accelerated partial breast irradiation (APBI) was not considered a suitable option based on the patient's age, BRCA 1/2 status, and extensive intraductal component (EIC). Instead of opting out of radiation treatment completely, the patient chose to pursue CyberKnife treatment.

CyberKnife is being used by multiple centers to treat early stage breast cancer. The ability of the CyberKnife System, using Synchrony® Respiratory Tracking, to track the tumor as it moves with respiration and automatically correct the beam aim in real-time allowed the diameter of the treated region to be reduced from 2.5 cm, used in APBI, IMRT and 3DCRT, to 1.8 cm or less with CyberKnife. This could decrease the risk of side effects by eliminating more normal tissue from the high-dose volume.



Post-lumpectomy MRIs (pre-Cyberknife treatment).

PARTIAL BREAST IRRADIATION AFTER LUMPECTOMY

TREATMENT DETAILS

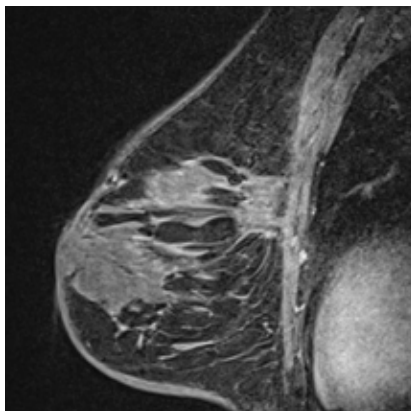
Target Volume:	CTV = 55.5 cm ³ PTV = 92.1 cm ³ Lumpectomy cavity = 16 cm ³	Fractions:	5 fractions
Imaging Technique(s):	CT + MRI	Path Template:	Short
Rx Dose & Isodose:	30 Gy delivered to the 70% isodose line	Tracking Method:	Synchrony® Respiratory Tracking
		Collimator:	25 mm
		Number of Beams:	112

Treatment Planning

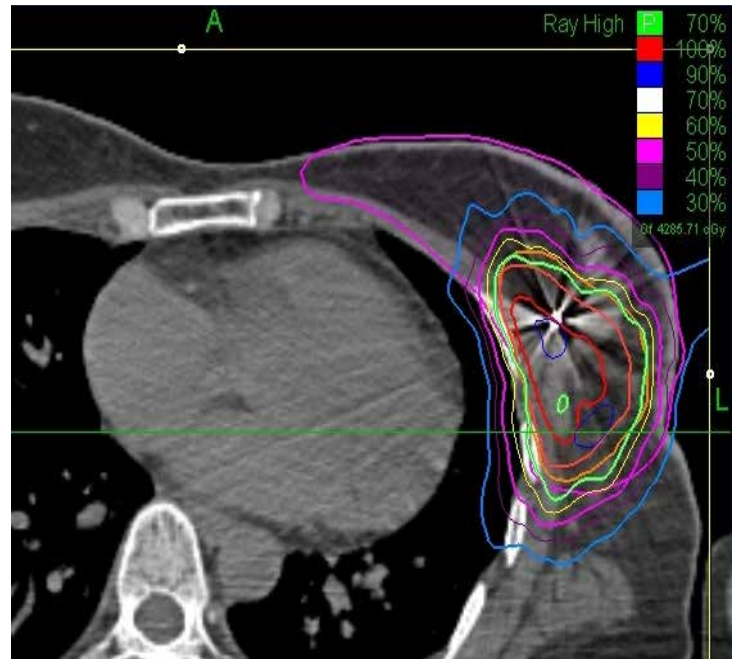
The treatment plan was developed using the MultiPlan® Treatment Planning System, and was based on a single-path, fiducial tracking algorithm. Four fiducials were implanted during the lumpectomy and were identified on the CT images. Treatment volumes were created by first outlining the resection cavity, resulting in a volume of 16 cm³. The resection cavity was expanded 15 mm isotropically to create the clinical target volume (CTV), except posteriorly where no expansion was applied because the cavity abutted the chest wall. The planning target volume (PTV) was created by expanding the CTV by 3 mm (except towards the chest wall, where no expansion was applied) to account for remaining uncertainty in target position. The final plan consisted of 112 non-zero beams and used one fixed collimator of 25 mm.

Treatment Delivery

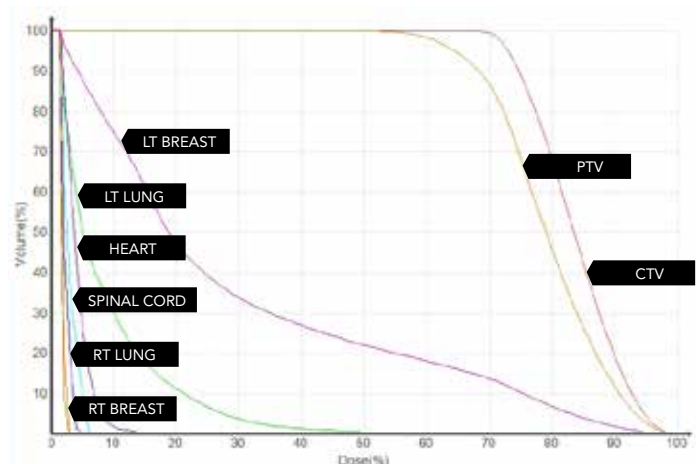
The patient was treated with the CyberKnife® System, which precisely targeted multiple non-isocentric, non-coplanar beams at the tumor bed. A large dose of radiation was delivered to a small field while sparing lung and cardiac tissues, as well as other critical structures. A prescription dose of 6.0 Gy per fraction was delivered in 5 fractions for a total dose of 30 Gy to the 70% isodose line. Synchrony Respiratory Tracking was used to track and correct the motion of the target due to respiration. The patient tolerated the treatment well, and reported no complaints due to treatment.



MRI 5 months post-CyberKnife treatment.



Axial planning image showing the lumpectomy bed, lung, heart and isodose curves.



Dose-volume histogram (DVH) showing the dose delivered to the lumpectomy cavity and organs at risk.

PARTIAL BREAST IRRADIATION AFTER LUMPECTOMY

Outcome and Follow-Up

- Almost 3-1/2 years after treatment the patient has had no complaints referable to treatment. She specifically denied any breast tenderness, chest wall pain, or overlying skin changes. There was no lymphedema of the arm and/or breast.
- The patient's mammogram and MRI scans, 41 months after treatment, were negative for cancer recurrence. Morphologic appearance of the breast parenchyma, on MRI, appeared relatively unchanged as compared to prior examinations. No abnormal internal mammary or axillary lymph nodes were identified.
- Physical exam revealed an excellent cosmetic result, with no palpable abnormalities in either breast, no discharge from either nipple, and no peripheral lymphadenopathy.

Conclusion

- Upon completion of the treatment no skin toxicity was noted.
- Almost 3-1/2 years after Cyberknife® treatment the patient had no complaints referable to treatment; specifically no skin toxicities or lymphedema were noted.
- CyberKnife radiosurgery, in conjunction with Synchrony® Respiratory Tracking, precisely delivers the prescription dose over a much shorter course of treatment than conventional radiotherapy.

SWEDISH RADIOSURGERY CENTER, SEATTLE, WA (www.swedish.org/radiosurgery)

Swedish Radiosurgery Center, formerly Seattle CyberKnife, was the first center in the Pacific Northwest to offer the CyberKnife radiosurgery option. The team of experienced physicians, physicists, and clinical staff has been instrumental in developing disease-specific treatment protocols, including protocols for breast and prostate cancer. The ability to track movement in real-time offers patients precise radiation delivery with outstanding results.

To contact the Swedish Radiosurgery Center, call 206-320-7130.

